SPORTS INJURIES

Daily physical exercise has become more vital than ever in today's world where many people are desk-bound workers who drive to work and barely walk in day to day life. While regular exercise and physical activity are crucial for maintining good health, injuries are common both for amateur and professional athletes. These injuries have a wide spectrum. Athletes may experience minor injuries lasting just a few days. However, they may be injured severely and treated operatively. Recovery period may take very long causing the athlete to be deprived of sports activities and training for a massive amount of time. Such injuries can even lead to cessation of a sports career. Correct diagnosis must be made and appropriate treatment should be applied to avoid permanent disabilities.

ISBN: 978-2-490773-51-0
9 782490 773510
LIVRE DE LYON
/www.livredelyon.com
/livredelyon
/livredelyon
/livredelyon

SPORTS INJURIES

SPORTS INJURIES

health

LIVRE DE LYON
Lyon 2020

LIVRE DE LYON

SPORTS INJURIES

LIVRE DE LYON

Lyon 2020

Editor- in-Chief • Esin Derin Cicek, MD.

Associate Editor • Barıs Yılmaz, MD, Assoc. Prof.

First Published • © 2020, Lyon

ISBN • 978-2-490773-51-0

Publisher

Livre de Lyon

Adress: 37 rue marietton, 69009, Lyon France
website: http://www.livredelyon.com
e-mail: livredelyon@gmail.com

LIVRE DE LYON

Editor- in-Chief Esin Derin Cicek, MD

University of Health Sciences. Fatih Sultan Mehmet Training and Research Hospital, Istanbul-TURKEY (Deputy Chief Physician)

Deparment of Radiology (head of musculoskeletal system division)

Associate Editor: Barıs Yılmaz, MD, Assoc. Prof.

University of Health Sciences. Fatih Sultan Mehmet Training and Research Hospital, Istanbul-TURKEY

Department of Orthopaedic Surgery and Traumatology

PREFACE

Daily physical exercise has become more vital than ever in today's world where many people are desk-bound workers who drive to work and barely walk in day to day life. While regular exercise and physical activity are crucial for maintining good health, injuries are common both for amateur and professional athletes. These injuries have a wide spectrum. Athletes may experience minor injuries lasting just a few days. However, they may be injured severely and treated operatively. Recovery period may take very long causing the athlete to be deprived of sports activities and training for a massive amount of time. Such injuries can even lead to cessation of a sports career. Correct diagnosis must be made and appropriate treatment should be applied to avoid permanent disabilities.

The mechanism of the trauma is very critical while diagnosing sports injuries. The athlete or a witness to the injury should be questioned to obtain information about the trauma mechanism. Furthermore, radiological methods are particularly useful. For accurate diagnosis, radiologist must be informed about the trauma mechanism. Early diagnosis is crucial for effective treatment. Missed cases tend to show up in clinic with chronic problems later on.

Sports injuries include more than just acute traumas. Microtraumas and overuse injures are also sports injuries and they may lead to chronic pain and loss of functionality. Sports injuries are common among professional athletes; however, people who sport in gyms and parks or at home may also suffer from these injuries. Tendonitis, muscle sprain and spasm, even meniscus or ligament ruptures are some of the traumatic pathologies associated with such sports activities.

This publication is designed to inform healthcare professionals in all medical fields. The aim was to compile useful information about sports injuries by dividing it regionally and deliver it to anyone interested. Trainers and sports instructors may also benefit from this book.

I would like to express my deepest appreciation to *Dt. Prof. Fulya Özdemir* who put her best effort in English editing of this book. I am also grateful to all my colleagues who contributed in production of this publication. I want this book to be considered as a gift to all health care professionals who had to stay away from their beloved ones during the COVID-19 Pandemic.

I hope that this book, which is presented to the use of the scientific community on an international platform, will be useful and you will always be able to find an opportunity for sports in your life. I express my gratitude

to all healthcare workers who struggle with great sacrifices in the world and in our country during the Covid 19 pandemic.

Best regards,

Esin Derin Cicek, MD

CONTENTS

IV. REHABILITATION PROCESS AND PSYCHOLOGY IN ATHLETES

I. UPPER EXTREMITY PROBLEMS IN ATHLETES

1.SHOULDER

Mustafa Vezirhüyük, MD

University of Health Sciences, Fatih Sultan Mehmet Training and Research Hospital, Department of Orthopaedic Surgery and Traumatology, Istanbul-Turkey

Nazım Karahan, MD

Çorlu State Hospital, Department of Orthopaedic Surgery and Traumatology, Tekirdag-Turkey

Bekir Eray Kılınç, MD, Assoc.Prof.

University of Health Sciences, Fatih Sultan Mehmet Training and Research Hospital, Department of Orthopaedic Surgery and Traumatology, Istanbul-Turkey

1.1. Introduction

The shoulder consists of the glenohumeral, sternoclavicular, acromioclavicular and scapulothoracic joints between the calvicula, scapula and humerus bones. With individual movement capability of each joint, the shoulder is the most mobile joint in the body, and also the joint most prone to injury (1).

The shoulder is capable of 6 movements; abduction, adduction, flexion, extension, internal rotation and external rotation. The active range of motion examination should be performed with the patient in sitting position. Patient moves his arms out to the side until his hands reach above the head (abduction). He moves his arms back down and cross them in front of the body (adduction). He moves his arms forward until his hands reach above the head (flexion). He moves his arms back down and swings them behind him (extension). He puts his both hands on the neck (external rotation). He extends his hands so as to touch the lower corner of the scapula (internal rotation) (1,6). In the passive joint range of motion

examination, the normal range of motion is 180° for abduction and 45° for adduction. Adduction is not important as abduction for clinical diagnosis. In case of subdeltoid bursitis and rotator cuff tendon lesions, adduction may be restricted. The normal range of motion is 180° for flexion and 45° for extension. The normal range of motion is 55° for internal rotation and 45° for external rotation. The passive range of motion is normal in tendinitis, rotator cuff tear, and cervical radiculopathies without capsulitis. Active movements may be restricted due to pain and/or weakness. The active and passive joint range of motion is reduced in shoulder periarthritis.

A combination of correctimaging and clinical examinationbefore treatment makes a positive contribution to the diagnosis and treatment outcome of shoulder problems. A four-direction shoulder radiography is sufficient for the initial exam. Depending on the clinical presentation, acromioclavicular joint radiography may also be required. While ultrasonography is especially important in full-thickness rotator cuff tears, computerized tomography becomes important in the presence of bone lesions. Any bone defect can be easily identified and measured. Especially using the three-dimension option, the shape and location of the fracture can be determined. Although Superior Labrum Anterior and Posterior (SLAP) lesions, rotator cuff tears and labral lesions can be identified by CT artrography, Magnetic Resonance Imaging (MRI) is the most commonly used method for the assessment of shoulder problems nowadays (1,2).

1.2. Neurovascular compression syndromes of the shoulder

It is seen especially in peopledealing with sports, where mainly the upper extremity is used (barbell, barfix, body-building etc.). The first-step in radiological evaluation is to take aradiograph to determine any bone deformity. If needed CT may be prescribed in determining bone anomalies which cannot be determined by radiography. If there is any soft tissue

injury, MRI is one of the most useful techniques. However, depending on the existing symptoms, CT-Angiography, Arterial and Venous Doppler US, Angiography, Venography and Electromyography (EMG) may be used. The treatment may include non-steroid anti-inflammatory drugs, activity restriction and local injections. Physical treatment may be tried, but it may increase the pain; which will result in the discontinuation of the treatment. Surgical treatment is carried out,if the patient does not respond to conservative methods.

Thoracic outlet syndrome (TOS)

In thoracic outlet syndrome, the subclavian artery, subclavian vein and brachial plexus are the structures subjected to compression, and the patient's complaints vary depending on these structures. The patients suffer neck and arm pains, hand paresthesia, which get worse when lifting arm, reaching overhead, and carrying weight. Pain is most often felt in the ulnar dermatome. In the artery compression, claudication-coldness, numbness and fatigue are seen; while, in the venous compression, pain, edema, heaviness and cyanosis are monitored. Since it was reported that the symptoms have got worse in 10-20% of the patients after the physical therapy, patients should be carefully followed up in the meanwhile (3).

Subclavian artery aneurysm

Subclavian artery stenosis and aneurysm occurs as a result of subclavian artery compression in the 1st costa level, while it almost always occurs in conjunction with congenital cervical rib or atypical 1st costa. It is usually asymptomatic until distal embolism occurs. When the distal embolism occurs, occlusion is seenin brachial, radial, ulnar and digital arteries. It is often diagnosed incidentally until becoming symptomatic. Although intraarterial thrombolytic treatment is helpful, early surgical thromboembolectomy is the most efficient treatment. After an early

surgical treatment, the patient can go backto sports within a few months, while ischemic problems in hand and fingers of late cases may not be completely eliminated.

Suprascapular nerve entrapment syndrome

The suprascapular nerve is a peripheral nerve with motor and sensory fibers that arises from the C5-C6 nerve roots and emerges from the upper trunk of the brachial plexus. Suprascapular neuropathy-related shoulder pains are seen secondary to trauma in athletes, and the repetitive stretching of the nerve, especially in those doing overhead movements such as volleyball players, baseball players, basketball players and dancers, is considered as an etiological factor.It often manifests itself as a blunt and well-localized pain located in the lateral and posterior of the shoulder. Shoulder external rotation and abduction are particularly weakened on the affected side, and this is usually confused with cervical disc pathologies. The pain may radiate to the neck and the front wall of the rib cage. The patient's history may have trauma and recurrent micro-traumas. In traumatic cases, the history of falling on an outstretched arm is common (4).

Quadrangular space syndrome

It occurs as a result of repetitive shoulder abduction / external rotation strains during sporting activities (9). This syndrome is characterized by posterior humeral circumflex artery and axillary nerve compression with the shoulder in abduction and external rotation. This can be caused by dynamic compression as well as proximal humerus and scapula fractures, concomitant hematoma / posteroinferior paralabral cyst, teres minor muscle hypertrophy or secondary to fibrous band (4). The patient has poorly localized lateral and posterior shoulder pain. The pain becomes apparent at night, after overhead activities and in the late phase

of throwing. In physical examination, teres minor and deltoid muscle atrophy is apparent. Direct palpation reveals pain in the quadrangular space (3,4). It is typical to see external rotation weakness and increased pain against resistance when the arm is in abduction. Minimal axillary neurosensory defect may be detected.

Scapular dyskinesis

It can be defined as medial scapular border prominence during the shoulder movement. It is presented as early scapular elevation duringarm extension, early downward rotation of scapula during lowering of the arm (5,6).It presents in as many as 67% to 100% of athletes, but it is usually asymptomatic. It is more common in athletes dealing with overhead activities. The clinical signs usually depend on the underlying cause (7). It is very important to get these athletes to gain normal scapular kinematics and to undergo a rehabilitation process (5,6).

Snapping scapula

It is a clinical picture with crepitation and pain radiating along the medial corner of the scapula. Although its exact mechanism is unknown, it is thought that soft tissue pathologies and skeletal problems involving the scapulothoracic joint cause pain and crepitation. Minor trauma, repetitive overhead activities and overuse are the probable causes (5).The most apparent characteristics are crepitation under the scapula, palpable soft-tissue nodules, trigger points and grinding sound. Temporary pain control by local anesthetic and steroid injection into the scapulothoracic bursa is important for both diagnosis and treatment prognosis. Physical therapy methods provide temporary pain control in chronic cases; however, relapse is a common problem (5-7).

Scapulothoracic bursitis

It is frequently seen with snapping scapula. Swelling and inflammation may occur in the bursa, and there is palpable crepitation with motion of the scapula. It may develop especially in pitchers with repetitive overhead activities (6).

1.4. Rotator cuff problems

Rotator cuff disorders range from mild compression to total tear. The tear usually occurs on the bursal surface. Especially, in athletes engaged in heavy sporting activities, the tear occurs in the articular surface. The major complaint of the patients is pain. They usually experience pain disturbing sleep at night. They feel intense pain with overhead reaching activities. In the radiographic examination, it is checked if there is alteration on the joint surfaces. USG is recently used for diagnosis. The best diagnostic method is MRI, which provides detailed information on the shape and size of the tear as well as showing concomitant other soft tissue and osseous pathologies. (Figure 1). Asymptomatic full-thickness tears should be treated conservatively. Patients who are non-compliant with treatment, and those at increased risk of surgical complications should be treated conservatively. For these patients, rehabilitation is planned for activity modification and rotator cuff strengthening. Supplementary drug therapy may be prescribed such as anti-inflammatory drugs and subacromial injection treatment may be administered. In young patients who are eligible for surgery, symptomatic tears may be treated surgically (7).

1.5. Muscle tears

Tear of other muscles around the shoulder other than rotator cuff is rare. They usually occur as sports-related injuries.

Pectoralis major rupture may occur during sports activities such as weight training, boxing, windsurfing, jujutsu. In body building, the pectoralis major muscle is one of the most commonly exercisedmuscle for functional and cosmetic reasons. Rupture may occur subsequent to maximal eccentric contraction of the muscle. A majority of the ruptures (47-70%) was reported to have occurred when doing the bench-press during training (8). It may be usually diagnosed by clinical observation and examination. MRI or USG imaging methods are helpful in determining the location and degree of the rupture. The symptoms include shoulder pain, swelling, ecchymossis, and palpable muscle defect in axillary web. Pain and weakness are present in adduction and internal rotation of the shoulder. Partial pectoralis major tears may be treated conservatively. The patient is followed up with the arm-shoulder in a sling (6). Active and passive exercises can be started at the end of the first week (9). Full-thickness tears, especially tendon avulsion type tears, should be treated surgically.

Deltoid tears are uncommon injuries. They are more frequently seen especially in population of elder veteran athletes (10). It usually occurs as partial tear. During rotator sheath operations, the deltoid muscle may be subjected to iatrogenic injury. It is often treated conservatively.

Another type of injury that may occur around the shoulder is rupture of the latissimus dorsi muscle. It is very rare. Pain is present in adduction and internal rotation of the shoulder. The conservative treatment outcomes are good. For high-capacity elite athletes, surgical treatment may be required (11).

1.6. Biceps tendon problems and slap lesions

Tendinopathy of the long head of the biceps is commonly encountered as a source of shoulder pain. Isolated biceps tendinopathies account for about 5% of biceps tendinopathies (Figure 2), while the

remaining 95% coexists with other shoulder disorders such as rotator sheath damage, SLAP lesions, adhesive capsulitis (12,13). The pain typically is in anterior of the shoulder. It may get worse with overhead movements such as lifting arm, throwing. It gets worse with palpation over the bicipital groove. The patient may not have a certain history of trauma (13). MRI is useful for diagnosing biceps tendinopathy and other concomitant pathologies of the shoulder. The patient is initially treated conservatively. The conservative treatment options include nonsteroidal anti-inflammatory drugs, physical therapy, resting, subacromial and glenohumeral corticosteroid injections and cold application. For the patients with tendinopathy of the long head of the biceps, who do not response to the conservative treatment, surgical treatment (tenotomy or tenodesis) is considered (14,15).

Superior labrum anterior posterior (SLAP) lesions are the pathologies characterized by the detached superior labrum and the biceps tendon anchor from anterior to posterior. It accounts for 5% of all shoulder injuries. Shoulder pains may have insidious onset or sudden onset following a trauma. The diagnosis of SLAP lesions is not always easy. SLAP lesions may be missed even on standard MRI. Thus, MR arthography is more efficient in detection of SLAP lesions. Treatment is primarily in favor of conservative treatment. When deciding a surgical treatment, the type of SLAP lesion, the age and activity level of the patient should be considered.

1.7. Shoulder instabilities

The shoulder joint stability depends on static and dynamic factors. The static factors include bone structure, cartilage, glenoid labrum, glenohumeral ligaments and capsule. Other factors contributing to the stability include the adhesion/cohesion effect between the cartilage

surfaces and the negative intra-articular pressure (16-18). Shoulder instabilities can be classified into 3 groups (19, 20).

Anterior Shoulder Instabilities

It is one of the most common shoulder injuries. It occurs when the loads on the shoulder exceed the strength of the elements of shoulder stability. Acute anterior shoulder dislocation usually results from the humeral head falling outside the glenoid by forcing the anterior capsule and the labrum mainly due to abduction, extension and external rotation (Figure 3). Rarely, anterior shoulder dislocation may occur as a result of a posterior force applied to the shoulder. The rate of recurrent dislocation decreases with increasing age (90% rate of recurrence in those younger than the age of 20). Dislocations may be acute (the patient presents up to two weeks) or chronic (if the patient presents later). Traumatic anterior dislocations may be accompanied by neurovascular injuries. The pathologies accompanying dislocation are as follows;

- **Bankart lesion:** Following an anterior shoulder dislocation, the labrum is detached from the anterior inferior glenoid in 85-97% of cases. This is called a Bankart lesion. Sometimes, this detachment involves the bone, which is known as “osseous Bankart”. Since the anterior labrum is the primary structure that resists forward loading, it is the most damaged structure in anterior dislocations (21,22).
- **Hill-Sachs Deformity:** The dislocation event pushes the humeral head anteriorly into contact with the dense anterior glenoid causing a compression fracture along the posterosuperolateral aspect of the humeral head (21,22) (Figure 3).
- **HAGL (Humeral avulsion of the glenohumeral ligament) lesion:** It defines the avulsion of the inferior glenohumeral

ligament from the humeral head. The rate of accompanying rotator cuff tear increases with increasing age; it is rare below age 20, while it reaches 30% above age 40 and 80% above age 60 (21-23).

- **ALPSA (Anterior labral periosteal sleeve avulsion) lesion:** Differently from the Bankart lesion, it is a lesion characterized by the anterior labroligamentous complex attached to the glenoid neck and healed medially.

In acute dislocations, the diagnosis is made by radiography. CT shows any accompanying bone injuries better than radiography. MRI reveals muscle, tendon and ligament injuries, and labral tears. Shoulder dislocation is a condition that should be promptly reduced. This reduction can be performed by specialists or well-trained persons. However, there are two important considerations. The first one is to avoid using excessive force for the reduction, not to causea fracture, and the second one is to prevent any nerve damage. If it is decided to administer conservative treatment based on the evaluation of the existing pathologies following reduction, the shoulder is immobilized. The length of immobilization is 2-4 weeks. During the immobilization of the shoulder, the motion capability of the wrist and hand joints should be maintained. Regardless of the length of immobilization, the range of motion, strength and functions of the joint will reduce following the immobilization period. At the end of immobilization, the patients should be included in a physiotherapy program with rotator cuff strengthening and scapular stability exercises (24). Early mobilization will prevent the formation of adhesions which may put the motion capabilities of the arm at risk.

Chronic shoulder dislocations are frequently encountered with a recurrent and concomitant pathology. Re-dislocation of the shoulder is not only a source of pain and sadness for the patient; but it may also result in revenue loss for those who earn their life using their upper extremity such

as athletes, who may encounter confidence loss in sport activities, and post-traumatic osteoarthritis. The risk of osteoarthritis following a shoulder dislocation is 20 times higher than a normal shoulder, which further increases with increasing number of dislocations. The treatment method for the first shoulder dislocation should be decided considering the possibility of repetition of the cause. The treatment methods shouldbe patient specific, regarding the potential complications following the surgical treatment (15).

Posterior Shoulder Instabilities

Posterior shoulder dislocations and recurrent posterior shoulder instability are very uncommon. The patients may present with complaints of recurrent posterior subluxation and acute dislocation. On the other hand, recurrent posterior subluxation is the most common type of posterior instability. Posterior dislocation may occur as a result of direct impact to the front side of the shoulder and falling on the extremity with the shoulder in flexion position as well as conditions causing loss of consciousness such as epileptic seizure, electrical shock, and intoxication (19,20). Recurrent posterior dislocation symptoms are similar to other shoulder problems, making definitive diagnosis difficult. As with most shoulder problems, the most common complaint is pain. The pain is related to loading the humeral head on the glenoid corner or the excessive stress exerted by the rotator cuff to maintain the humeral head centered in the glenoid. Patients with posterior subluxation describe a catching sensation or crepitation when the shoulder dislocates in certain positions (19). In radiological evaluation, diagnosis can be made using serial radiography, however CT is more useful. Conventional arthrography and MR arthrography are the most reliable diagnostic methods due to their capability to show labral and capsular pathology (16,19). The first-line treatment should be conservative treatment. The conservative approach is to teach the patient to avoid

activities that may cause dislocation and unintentional movements that may cause subluxation. The main purpose of the treatment is rehabilitation of the external rotators, especially the infraspinatus muscle. Muscle strengthening is more effective in posterior instability than anterior, but success is not achieved in all patients. However, normal range of motion should be retrieved. Especially in most shoulder instabilities arising from generalized ligamentous laxity and recurrent microtraumas, the patients receive great benefit from an intensive exercise program (16,17). If success cannot be achieved by an appropriate rehabilitation program of 4-6 months, surgical intervention may be indicated.

Multidirectional Shoulder Instabilities

Multidirectional shoulder instability may be of structural and functional origin. The structural causes include anatomical alterations of the humeral head or the glenoid, and joint relaxation. In case of joint relaxation, there is excessive shoulder displacement in many directions, but if it does not cause clinical complaints, it is called laxity. The laxity turns into an instability presentation with emerging clinical symptomsdue to further trauma or overuse (12,13). Multidirectional shoulder instability is a presentation characterized by pathological multidirectional displacement of the humeral head inside the glenoid. For many patients, the only complaint is shoulder pain in addition to recurrent semi-dislocations or dislocations. The basis of the diagnosis is history and physical examination. In rare cases, radiological examinations help in the diagnosis. It cannot be detected in all patients, even if excess posterior and inferior displacement is a classic finding in the examination. Radiological examinations usually provide indirect information. Besides bone problems revealed by radiography, MRI is used to detect special lesions in the presence of shoulder instability. The basic treatment approach is conservative treatment. The basis of physical therapy is to strengthen the

muscles around the glenohumeral joint and the scapula and to work them in a coordinated manner. The treatment is considered successful if the patient's complaints disappear after the physical therapy and the patient returns to sports. However, the patients commonly refer to a physician with recurrent complaints. Especially in athletes, the alleviated complaints following physical therapy and resting reappear sometime after going backto sports. The goal of physical therapy is to ensure the humeral head to return to the center of the glenoid and to regain its normal functions (13,14). Surgical treatment is applied for cases who do not respond to physical therapy (13,15).

1.8.Calcific tendinitis of the shoulder

It is one of the common and important causes of shoulder pain. It is more commonly seen in women and in ages 30-60, however it was reported in 7.5-20% of adults without any complaint and 6.8% of those with shoulder pain. It mostly affects the supraspinatus tendon (80% of cases) (24). It was reported that it rarely affects the subscapularis tendon (5% of cases) (25). In case of calcific tendinitis, calcium deposits are localized in the tendon, causing a painful outcomewith movement restriction (26,27). The lesion develops slowly in a long process of time and tends to heal spontaneously with the spontaneous resorption of the reactive calcification after an unpredictable painful period. Sometimes, it causes no complaint and can be determined incidentally by radiographic examination. Clinically, the disease start acutely and then becomes chronic. Acute symptoms last for 2 weeks, sub-acute symptoms last for 3-8 weeks, and chronic symptoms last for 3 months or longer. The acute symptoms disappear within one-two weeks even without treatment. During sub-acute and chronic stages, the patients have usually complaints of pain and sensitivity. The range of motion of the glenohumeral joint is reduced due to pain. Diagnosis can be made by the clinical presentation and the

radiographs taken at appropriate position depending on the stage and the magnitude of calcification. CT, MRI and USG can be also used for diagnosis. Conservative approaches including joint rest, non-steroid anti-inflammatory drugs, analgesics and psychotherapy can be effective in treatment. Otherwise, needle aspiration, steroid and anesthetic injection, extracorporeal shock therapy can provide benefit. Conservative treatment is recommended for acute cases, and the primary goal is to reduce pain (28,29). Surgical treatment is recommended for chronic cases, because prolonged waiting may cause adhesive capsulitis.

Frozen shoulder

Frozen shoulder can be classified as primary or secondary. The primary frozen shoulder occurswith progressive restriction of active and passive shoulder movements and is more commonly seen in ages 35-70, women and non-dominant side. It is of unclear etiology; however, it was found associated with diabetes mellitus, autoimmune diseases, thyroid dysfunction, Dupuytren's contracture, autoimmune diseases and breast cancer. Secondary frozen shoulder that is more common in athletes is encountered as a result of macrotrauma, microtrauma, surgery and prolonged immobilization (30). It is believed that there are synovial inflammation of the joint capsule and subsequent fibrosis. Increased fibrosis decreases the shoulder joint volume, which results in movement restriction. Basically, it is characterized by 4 stages:

- **In the initial stage**; the patient has complaints of active and passive movement restriction. There is pain while resting and at nights, and after sudden movements. The symptoms persist for less than three months. Movement is lost progressively. Following examination under anesthesia and intra-articular local anesthetic

injection, the loss of movement is completely resolved or minimized.

- **In the freezing stage**; the symptoms persist for 3-9 months; there are chronic pain and progressive loss of movement. There is pain at nights and while resting, causing a serious sleep disturbance. Following intra-articular local anesthetic injection or scalene block, the movement loss may be partially resolved and the pain may disappear.
- **In the frozen stage**; the pain is minimal at night or while resting, but there is an apparent movement restriction. The symptoms persist for about 9-15 months. The range of motion does not change with local anesthetic injection or examination under anesthesia.
- **In the thawing stage**; there is a progressive improvement in shoulder movements with minimal pain.

Clinical evaluation, history and radiological examination are required for diagnosis. The complaints in the first stage of the disease is often similar to 'impingement syndrome'. Many patients have no trauma history. There is usually an insidious-onset pain, which induces movement restrictions of the shoulder (31). Routine radiographs are taken to eliminate other pathologies. They are usually normal; however, osteopenia may be observed in some cases. MRI is used to detect other pathologies such as rotator cuff tear; yet it is not a method that is routinely used to diagnose frozen shoulder. MR arthrography is useful for viewing the capsule thickness and the reduced joint volume. Doppler Ultrasonography is used to evaluate inflammatory changes in soft tissue and vascularity (32,33).

Before treatment, it is important to determine the stage of the disease for success. Although the natural course of treatment has not been

completely revealed for patients with frozen shoulder, it was reported that it can heal within 2-3 years in average (34). The purpose of the treatment is to control pain whichis the major complaint of the patients, and to restore the motion capability and power of the joint. The initial treatment method is conservative treatment. With physical therapy, it is aimed to recover the loss of range of shoulder motion. Nonsteroid anti-inflammatory drugs may be used in early inflammatory period to prevent inflammation and pain (34,35). Steroid injection may be used to suppress inflammation at the beginning of stage 1 and stage 2. Exercise combined with steroid injection into the glenohumeral joint is one of the most common combination today (35). If anti-inflammatory drugs, intra-articular injections, physical therapy or manipulations do not alleviate the patient's complaints, surgical treatment should be considered especially in stage 3 frozen shoulders.

1.9. Acromioclavicular and Sternoclavicular joint injuries

Acromioclavicular joint injuries usually result from a force applied downward on the acromion. The most common injury mechanism is falling directly on the shoulder. Other injury mechanisms include high-energy traumas such as falling from height, vehicle accident, direct trauma to the joint (36-38). A carefully taken medical history and physical examination are essential for diagnosis. In physical examination, the range of shoulder motion and neurovascular status are evaluated. Routine radiographs largely show acute dislocations, but sometimes additional radiographs taken from different angles may be required. CT is better to show concomitant intra-articular non-displaced fractures. It is the best method to show the direction and degree of displacement in case of fractures. MRI is used to view ligament injuries. Conservative treatment may include cold application, immobilization and non-steroid drugs if there is no excess dissociation. For cases who do not respond to the conservative treatment, surgical treatment

comes into prominence in case of the formation of chronic instability (37,38).

The sternoclavicular joint is an important joint for the shoulder girdle movements. Dislocation of the sternoclavicular joint is an uncommon injury and associated with high-energy traumas such as motor vehicle accidents. It is the most common anterior dislocation and results from an anterolateral force to the shoulder. Posterior dislocations are associated with a crushing force to the chest, and 25% of posterior dislocations are accompanied by injuries of superior mediastinal structures. The patients usually present with complaints of pain and deformity in the acute period following injury, while the only complaint may be deformity in the chronic period. Subluxation is usually painless and has no influence on daily activities. Therefore, it is usually thought to require no surgical treatment. Some patients may have pain in the forearm and shoulder, and fatigue and weakness in the arm. Since, there may be risk of compression to vital structures in case of posterior dislocations, symptoms such as dyspnea, stridor, dysphagia, paresthesia should be evaluated in examination. Furthermore, symptoms such as tachypnea, hypoxia, respiratory distress, difficulty controlling secretions, discoloration, swelling, and pulse loss in the affected limb should be also checked. The presence of these symptoms require surgical treatment. Radiographs taken at special positions (Serendipity graphy) are useful in determining the type of dislocation, which are the first step in imaging. Besides, the most reliable diagnostic method to determine the position of dislocation is three-dimensional CT or USG including comparison of both joints (39).

References:

1. Giacoma DG: Atlas of Functional Shoulder Anatomy. Editor; Giacoma DG, Springer Milan, Italy, 2008.

2. Memisoglu S, Yılmaz B, Aktas E, Kömür BH. Isolated scapula fracture: Ice hockey player without trauma. Annals of Medicine and Surgery, 4(3), 235- 237., Doi: 10.1016/j.amsu.2015.07.015

3. Poitevin LA. Thoracic outlet syndrome, scalene complex and interscalene passages. In: Tubiana R, Gilbert A, editors. Tendon, nerve and other disorders, 1st ed. London: Taylor & Francis 2005;p:321-32.

4. Post M, Mayer J. Suprascapular nerve entrapment: Diagnosis and treatment. Clin Orthop Relat Res 1987;(223):126-36.

5. Pearse EO, Bruguera J, Massoud SN, Sforza G, Copeland SA, et al.. Arthroscopic management of the painful snapping scapula. Arthroscopy 2006;22:755-61.

6. Tate AR, McClure P, Kareha S, Irwin D, Barbe MF. A clinical method for identifying scapular dyskinesis, part 2: validity. J Athl Train 2009;44(2):165-73.

7. Connell DA, Potter HG, Sherman MF, Wickiewicz TL. Injuries of the pectoralis major muscle: evaluation with MR imaging. Radiology. 1999;210:785-91.

8. Yu JS, Habib PA. Common injuries related to weightlifting: MR imaging perspective. Semin Musculoskelet Radiol. 2005;9:289-301.

9. De Castro Pochini A, Ejnisman B, Andreoli CV, Monteiro GC, Silva AC.Pectoralis major muscle rupture in athletes: a prospective study. Am J Sports Med. 2010;38:92-8.

10. Bak K, Cameron EA, Henderson IJ. Rupture of the pectoralis major: a meta-analysis of 112 cases. Knee Surg Sports Traumatol Arthrosc. 2000;8:113-9.

11. Lin JT, Nagler W. Partial tear of the posterior deltoid muscle in an elderly woman.Clin J Sport Med. 2003;13:120-2.

12. Friedman MV, Stensby JD, Hillen TJ, Demertzis JL, Keener JD. Traumatic Tear of the Latissimus Dorsi Myotendinous Junction. Case Report of a CrossFit-Related Injury. Sports Health. 2015;7(6):548-52.

13. Provencher MT, LeClere LE, Romeo AA. Subpectoral biceps tenodesis. Sports Med Artrosc 2008;16(3):170-6.

14.Churgay CA. Diagnosis and treatment of biceps tendinitis and tendinosis. Am Fam Physician 2009;80:470-6.

15. Pehlivan AT, Pehlivan E, Imren Y, Dedeoglu SS, Sarı A. Are we over-treating biceps tendon disorders? Medicine Science 2017;6(3):486-90.

16. Bankart AS. Recurrent or habitual dislocation of the shoulderjoint. 1923 Br Med J 1923;2(3285):1132-3.

17. Kim HS, Ha KI, Yoo JC, Noh KC. Kim's lesion: an incomplete and concealed avulsion of the posteroinferior labrum in posterior or multidirectional posteroinferior instability of the shoulder. Arthroscopy 2004;20(7):712-20.

18. Illyés A, Kiss RM. Electromyographic analysis in patients with multidirectional shoulder instability during pull, forward punch, elevation and overhead throw. Knee Surg Sports Traumatol Arthrosc 2007;15(5):624-31.

19. McFarland GE, Neira CA, Gutierrez MI, Cosgarea AJ, Magee M. Clinical significance of the arthroscopic drive-through sign in shoulder surgery. Arthroscopy 2001;17(1):38-43.

20. Luke TA, Rovner AD, Karas SG, Hawkins RJ, Plancher KD. Volumetric change in the shoulder capsule after open inferior capsular shift versus arthroscopic thermal capsular shrinkage: a cadaveric model. J Shoulder Elbow Surg 2004;13(2):146-9.

21. Liavaag S, Brox JI, Pripp AH, Enger M, Soldal LA. Svenningsen S. Immobilization in external rotation after primary shoulder dislocation did not reduce the risk of recurrence: a randomized controlled trial. J Bone Joint Surg Am. 2011;93(10):897–904.

22. Itoi E, Hatakeyama Y, Sato T, Kido T, Minagawa H, et al. Immobilization in external rotation after shoulder dislocation reduces the risk of recurrence. A randomized control study JBJS 2007;10:2124-31.

23. Akpinar S, Uysal M, Ozkoç G, Tandoğan NR. Thermal assisted arthroscopic stabilization of unstable shoulder. Acta Orthop Traumatol Turc 2005;39:96-102.

24. Bhargav D, Murrell GAC. Basic Science of Adhesive Capsulitis. Techniques in Shoulder & Elbow Surgery 2011;12(4):126-9.

25. Kurt KN, Aktaş İ, Yılmaz B. Acute calcific tendinitis of the subscapularis tendon: A rare case diagnosed by ultrasound imaging and terated succesfully. Archives of clinical case studies. 2018;1(1). DOI: 10.33552/ACCS.2018.01.000504

26. Lynch TS, Edwards SL. Adhesive capsulitis: current concepts in diagnosis and treatment. Current Orthopaedic Practice 2013;24(4):365-9

27. Neviaser JS. Adhesive capsulitis of the shoulder. A study of the pathological findings in periarthritis of the shoulder. J Bone Joint Surg Am 1945;27(2):211-22.

28. Lho YM, Ha E, Cho CH, Song KS, Min BW, et al. Inflammatory cytokines are overexpressed in the subacromial bursa of frozen shoulder. J Shoulder Elbow Surg 2013;22(5):666-72.

29. Xu Y, Bonar F, Murrell GA. Enhanced expression of neuronal proteins in idiopathic frozen shoulder. J Shoulder Elbow Surg 2012;21(10):1391-7.

30. Uhthoff HK, Boileau P. Primary frozen shoulder: global capsular stiffness versus localized contracture. Clin Orthop Relat Res 2007;456:79-84.

31. Sheridan MA, Hannafin JA. Upper extremity: emphasis on frozen shoulder. Orthop Clin North Am 2006;37(4):531-9.

32. Grasland A, Ziza JM, Raguin G, Pouchot J, Vinceneux P. Adhesive capsulitis of shoulder and treatment with protease inhibitors in patients with human immunodeficiency virus infection: report of 8 cases. J Rheumatol 2000;27(11):2642-6.

33. De Ponti A, Viganò MG, Taverna E, Sansone V. Adhesive capsulitis of the shoulder in human immunodeficiency virus positive patients during highly active antiretroviral therapy. J Shoulder Elbow Surg 2006;15(2):188-90.

34. Song KD, Kwon JW, Yoon YC, Choi SH. Indirect MR arthrographic findings of adhesive capsulitis. AJR Am J Roentgenol 2011;197(6):1105-9.

35. Walmsley S, Osmotherly PG, Walker CJ, Rivett DA. Power Doppler Ultrasonography in the Early Diagnosis of Primary/ Idiopathic Adhesive

Capsulitis: An Exploratory Study. J Manipulative Physiol Ther 2013;36(7):428-35.

36. Person MR, Leonard RB. Posterior sternoclavicular dislocation. J Emerg Med. 1994;12:783-5.

37. Cope R. Dislocation of the sternoclavicular joint. Skeletal Radiol. 1993;22:233-8.

38.Jeh CL, Williams GR. Conservative management of sternoclavicular injuries. Orthop Clin North Am. 2000;31;189-203.

39. Boolh CM, BA Roper. Chronic Dislocation of the sternoclavicular joint. An operative Repair. Clin. Orthop. 1979;140:17-20.

Figure 1. MRI, Coronal Image: Full-thickness rupture at rotator cuff (red arrow).

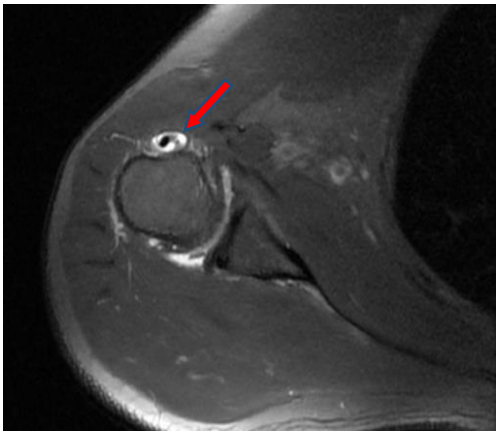

Figure 2. MRI, Axial Image: Fluid appearance in the biceps tendon sheath (biceps tenosynovitis, red arrow).

Figure 3. Anterior shoulder dislocation. A Hill-Sachs lesion is a compression fracture of the posterosuperolateral humeral head (red arrow, on the right image).

2.ELBOW JOINT

Fatih Aksay, MD

University of Health Sciences, Fatih Sultan Mehmet Training and Research Hospital, Department of Orthopaedic Surgery and Traumatology, Istanbul-Turkey

Ruhat Ünlü, MD

University of Health Sciences, Fatih Sultan Mehmet Training and Research Hospital, Department of Orthopaedic Surgery and Traumatology, Istanbul-Turkey

Demet Pepele Kurdal, MD

University of Health Sciences, Fatih Sultan Mehmet Training and Research Hospital, Department of Orthopaedic Surgery and Traumatology, Istanbul-Turkey

2.1. Introduction

Functionality of the human hand depends on the motion capabilities of the elbow, forearm and shoulder joints, and the loss of this functionality disturbs daily activities (1,2). The elbow joint is a joint that plays a very critical role in the motion capability of the upper extremity. The stability of the elbow is provided by the normal anatomy of the bones and the ligaments (3). The stability of the joint movements of the elbow is provided by full congruence of the joint surfaces, capsuloligamentous structures and dynamic stabilizers (muscles). The elbow joint is a hinge-type joint that consists of the humerus, radius and ulna bones and a thin joint capsule formed by the combination of the humero-ulnar, humero-radial and radio-ulnar joints, and can move in a single plane. It is located in distal of the humerus with trochlea in the medial side and capitulum in the lateral side, and contains two condyles; medial and lateral epicondyle. The medial epicondyle is more prominent, which forms the origin of the flexor and pronator muscle groups, together with the medial collateral

ligament, while the lateral epicondyle is less prominent, which forms the origin of the extensor and supinator muscle groups, together with the lateral collateral ligament (3,4). Carrying heavy objects, overuse of the wrist and elbow in rotational position (using screwdriver, knitting etc.), sports that force the wrist (tennis, golf etc.), traumas on the wrist and elbow may cause elbow pathologies.

2.2. Injuries of tendons and ligaments around the elbow

Injuries of tendons and ligaments around the elbow are common injuries especially in those dealing with sports that strain the upper extremity. Both diagnosis and treatment of these injuries is of great importance.

- **Triceps tendon injuries:** Triceps tendon ruptures are uncommon. It is more commonly seen in those dealing with weight training, middle-aged male population or debilitated patients. For the treatment of olecranon bursitis, local corticosteroid injection, anabolic steroid use, systemic diseases (Renal osteodystrophy, DM, RA, hyperparathyroidism) are risk factors for triceps tendon rupture. There may be posterior elbow pain, swelling and ecchymosis and weakness when the elbow is extended. Partial tears may be treated with splinting and immobilization. Full-thickness tears are treated by surgically.
- **Biceps tendon rupture:** Distal biceps tendon ruptures are uncommon injuries. It accounts for 3% of all tendon injuries (5). The patients are usually from physically-active, middle-age male population. It is more common in athletes dealing with weight training. It typically results from sudden forced extension while the elbow is in semi-flexed position. There may be pain, swelling in the antecubital fossa. In examination, the biceps cannot be

palpated in the anterior elbow. There is weakness when the forearm is in supinated position. Conservative treatment is recommended for elderly and sedentary patients. However, surgical treatment is recommended for young and physically active individuals.

- **Medial collateral ligament injuries:** It usually occurs due to a trauma or repetitive valgus stress of the elbow related to throwing sports such as javelin throw, baseball. MR arthrogram following examination is useful for diagnosis. Conservative treatment methods are considered first. The conservative treatments include resting, strengthening of pronator-flexor muscles. In cases where the conservative treatment fails, medial collateral ligament reconstruction is performed.
- **Lateral collateral ligament injuries:** This ligament complex consists of four components; lateral ulnar collateral ligament (LUCL), lateral radial collateral ligament (LCL), accessory lateral collateral ligament (ALCL), accessory ligament (AL). The primary stabilizer against varus force is LUCL.Chronic instability of the elbow results from an insufficient healing response to the lateral collateral ligament complex injury associated with the elbow fracture. There is pain and instability in the elbow. Conservative treatment is usually unsuccessful. A successful outcome may be achieved by LCL reconstruction (6).

2.3. Epicondylitis

Epicondylitis is an injury of the elbow which significantly restricts the activity especially in sports that require squeezing the hand. In particular, failure to achieve successful treatment during the period when

the sport activity continues may be a serious restrictive factor for the athletes.

- **Lateral epicondylitis:** It is one of the most common lesions of the arm, also known as “tennis elbow”, which is characterized by pain in the forearm extensor muscle surface and the lateral epicondyle from which the wrist extensors originate. It is seen in those engaging in activities involving repetitive challenging wrist extension, and leads to chronic pain syndrome (1,3). It may secondary to an acute trauma in the lateral epicondyle of the humerus as well as result from recurrent microtrauma of the extensor tendons. It causes micro-tears and micro-ruptures in the origin of the extensor carpi radialis tendon. Sport activities, use of hammer, lifting heavy, tight gripping as well as obesity and smoking are also accused. Following this mechanical injury, a secondary inflammation occurs in the epicondyle. The tendon is edematous and fragile. Its course is usually chronic (3,7). Localized pain exists on the lateral epicondyle on the outside of the elbow, and may radiate to the forearm or the arm. The pain gets worse with wrist movements especially dorsiflexion (7,8). Today, there are many treatment options for the lateral epicondylitis. The purpose of the treatment is to eliminate the local inflammation and pain. Thus, the traumas causing the lateral epicondylitis should be eliminated. Resting, activity modification, non-steroid anti-inflammatory drugs, PRP, local steroid injection, therapeutic ultrasound, phonophoresis, cold application, banding and stretching exercises provide benefit. Wrist braces that hold the wrist in extension position and epicondylitis braces used for the forearm muscles reduce the load at the lateral epicondyle, making contribution to the treatment. These braces can be used during the

activities that provoke the pain. For the patients who have not benefited from these conservative treatment methods for about 4-6 months, surgical treatment should be considered (1,3,7-9) (Figure 1).

- **Medial epicondylitis**; It is a tendinopathy that occurs in the attachment of the flexor-pronator muscle group onto medial of the elbow. It may occur in workers who perform repetitive challenging activities such as carpenters, road workers, and athletes such as golf/bowling players. These repetitive stresses, especially applying a valgus force with the forearm pronated, cause tension and degenerative changes in the elbow flexor muscles (1,3).The injury and pain mechanism are very similar to that of the lateral epicondylitis. There is also chronic inflammation due to direct trauma or chronic recurrent micro-traumas (1,3,7).The basic symptom of medial epicondylitis is medial elbow pain. The pain may radiate to the forearm and gets worse with forearm and wrist movements. Due to pain, the grip force is usually reduced. Resistant wrist flexion and 90-degree forearm pronation provoke the pain. The diagnosis is easily made by the clinical findings. The treatment principles are similar to that of lateral epicondylitis.

2.4. Elbow osteonecrosis

Osteonecrosis of the elbow joint is often missed. Due to poor blood supply to the articular cartilage, the elbow joint is very sensitive to this condition. The blood supply to this region can be easily impaired, which usually causes osteonecrosis due to the lack of blood supply to the proximal part of the bone (10-12). It is more common in men, except for those that occur secondary to collagen-vascular diseases in middle-age patients. Trauma is an important factor in younger patients. The chief

complaint of the patients is pain on the affected elbow joint or radiating to the adjacent joints. The patients have pain that gets worse with a deep palpation on the elbow joint, and reduced range of motion of the affected joints. The pain may get worse with active and passive movements. Crepitation may be also elicited during these movements. The reduced range of motion of the joint is the typical finding, which is correlated with the progress of the disease (12-14). Diagnostic radiography is indicated for all patients with suspected elbow osteonecrosis in order to exclude any underlying bone pathologies and to identify the bone component on the joint surface. However, direct graphy is usually not reliable in early stages of the disease. MRI is valuable for diagnosing the alterations of the joint surface earlier than radiography. MRI should be performed in cases with suspected joint instability, infection and tumor or for all patients whom radiographies are not sufficient for diagnosis. With a gadolinum-based MRI, the blood supply to the elbow joint can be viewed, with contrast enhancement of the elbow joint being a good prognostic sign (10-13).3D-CT may be useful in early diagnosis. As initial treatment, NSAID is used for pain control. Since the complaints may get worse, avoiding lighting heavy and exercises which may force the elbow joint is one the first steps in treatment. Hot-cold treatment is useful for palpation. For the patients who do not respond to the initial treatment, a local anesthetic injection to the elbow joint may help relieving the acute pain. The patients who do not respond to those are treated surgically (13,14).

References:

1. Celli A. Anatomy and Biomechanics of the Elbow. Ed: Celli A. Celli L. Morrey BF. Treatment of Elbow Lesions New Aspects in Diagnosis and Surgical Techniques 2008;p:1-11.

2. Kilinc BE, Celik H, Oc Y, Unlu R, Keskinoz EN, Yilmaz B. Analysis of Subcutaneous Anterior Transposition versus in-situ Decompression of Ulnar Nerve with Force Transducer in Cadaver Specimen. Turk Neurosurg. 2020;30(1):99-103.

3. Nirschl RP, Ashman ES. Tennis Elbow Tendinosis (epicondylitis) Nirschl Orthopedic Sports Medicine Clinic, Virginia Hospital Center, Arlington, Virginia, USA Instructional Course Lectures 2004;53:587-98.

4. Fornalsky S, Gupta R, Lee TQ. Anatomy and Biomechanics of the Elbow Joint. Techniques in Hand and Upper Extremity Surgery 2003;7(4):168-78.

5. Tarallo, M Lombardi, F Zambianchi, A Giorgini, F Catani. Distal biceps tendon rupture: advantages and drawbacks of the anatomical reinsertion with a modified double incision approach. Tarallo et al. BMC Musculoskeletal Disorders 2018;19:364.

6. MC Mica, P Caekebeke, R Van Riet, Lateral collateral ligament injuries of the elbow-chronic posterolateral rotatory instability (PLRI). EFORT Open Rev. 2016 Dec;1(12):461-8.

7. Aktas E, Yılmaz B, Ataoglu MB, Arıkan M, Togral G, et al. The Efficacy of Platelet Rich Plasma Combined with Steroid Injection

in the Treatment of Resistant Lateral Epicondylitis. Acta Oncologica Turcica 2014;47(3):26-31.

8. Goguin JP, Rush Fr. Lateral Epicondylitis. What is it really? Current Orthopaedics 2003;17:386-9.

9. Tosun HB, Gümüştaş S, Ağır İ, Uludağ A, Serbest S, Pepele D, Ertem K. Comparison of the effects of sodium hyaluronate-chondroitin sulphate and corticosteroid in the treatment of lateral epicondylitis: a prospective randomized trial. Journal of Orthopaedic Science 2015;20:837-43.

10. Waldman SD: Atlas of Uncommon Pain Syndromes Osteonecrosis of The Elbow Joint 2019;40:113-4.

11. Henderson AB: Sickle cell anemia: clinical study of fifty-four cases (review) Am J Med 1950;9:757-65.

12. Mukaza MM, Manicom O, Fillipini P, Hernigou P. Elbow osteonecrosis in sickle cells anemia: a study of six cases, Orthop Traumatol 2009;95:82-4.

13. Waldman SD: Osteonecrosis of the elbow. In Waldman SD, Campbell RSD, edi- tors: Imaging of pain. New York, 2011;p:281-3.

14. Watanabe R, Sato K, Nakamura T, Obara Y, Toyama Y, Ikegami H. Steroid-induced osteonecrosis of bilateral distal humerus treated by arthroplasty using costal osteochondral graft: case report. J Hand Surg 2011;36:816-9.

Figure 1. Pain location at lateral epicondylitis (tennis elbow).

3. HAND AND WRIST

Emirhan Usta, MD

University of Health Sciences, Fatih Sultan Mehmet Training and Research Hospital, Department of Orthopaedic Surgery and Traumatology,İstanbul-Turkey

Ali Tufan Pehlivan, MD

University of Health Sciences, Fatih Sultan Mehmet Training and Research Hospital, Department of Orthopaedic Surgery and Traumatology,İstanbul-Turkey

Güzelali Özdemir, MD, Assoc.Prof.

University of Health Sciences, Ankara City Hospital, Department of Orthopaedic Surgery and Traumatology, Ankara-Turkey

3.1. Introduction

The wrist and hand are the body parts most prone to injury due to their motion capabilities for all athletes. The wrist has 3 motion axes; flexion-extension, radial-ulnar deviation and pronation-supination (1,2). The normal hand is capable of flexion, extension, radial deviation, ulnar deviation movements. As with all diseases, the first thing to do is a physical examination for diagnosis of hand and wrist diseases. Firstly, the skin is inspected. Any discoloration, rashes, spots, swellings should be noted. If any, muscle atrophies in the hand region should be noted. Deformities of the hand and wrist, angulation, rotation, missing/extra finger etc. should be inspected carefully (3). Findings such as mass, temperature difference, crepitus, effusion are evaluated. The range of motion of the wrist and hand joints should be examined. A possible restriction and laxity condition should be noted. Stability tests should be performed to detect a possible instability. Arteriogram or dublex Doppler USG methods are used to perform a vascular evaluation. Furthermore, a nerve examination should be performed.NVC (nerve conduction velocity) is used to check the nerve conduction. With this test, peripheral nerves are evaluated. The nerves'

response to electrical stimulation is evaluated (4). EMG (electromyography) test is used to evaluate the activities of motor units and the muscle fibers. Radiographs are used to detect osseosis pathologies in acute trauma. It is the first examination to be performed for the patient with trauma (1). However, CT is the gold standard to image osseosis pathologies and commonly used for the evaluation of intra-articular fractures (5). MRI is used for cases with suspected soft tissue pathologies. It is also used to evaluate avascular necrosis and non-displaced fractures of the bones with poor blood supply such as scaphoid (6).

3.2. Carpal fractures

Carpal fractures account for about 20% of all hand and wrist fractures. The most common carpal bone fracture is scaphoid, accounting for 70% of all carpal bone fractures (Figure 1). It commonly occurs in the active-young male population after a fall onto outstretched hand, which is very likely to occur in sports competition and trainings (7). The axial pressure force produced while the elbow is in hyperextension position lies behind the mechanism (8). However, carpal bone fractures are often missed during diagnosis. The most consistent symptom in physical examination is localized sensitivity. In particular, sensitivity of the anatomical snuff box (fovea radialis), pain with straight traction of the thumb, ecchymosis and edema are guiding indicators. In case of carpal bone fractures, radiographs are used first. In cases where the direct graphy is insufficient, CT and MRI may be also used. Instable carpal bone fractures are usually accompanied by ligament injuries (9,10). Depending on the stability status of the fracture, conservative or surgical treatment is decided. The union rate is high in early-diagnosed cases. In stable and non-displaced fractures, conservative treatment with plastering is usually preferred. The conventional treatment method involves immobilization for at least 6-8 weeks. In untreated fractures, nonunion, “hump deformity”,

avascular necrosis, collapse of carpal bones may occur. Due to restricted blood supply to the scaphoid bone fed by branches of the radial artery, the risk of avascular necrosis is very high (15-50%) in follow-ups.

The second most common carpal bone fracture after scaphoid fracture is tricuetrum fracture. These fractures may be accompanied by perilunate dislocations, and the presence of instability should be investigated (9,11). The 3rd most common carpal bone fracture is trapezium fracture. Capitatum, hamatum, pisiform and trapezoid fractures are rarely encountered in the daily clinic. For the stable, non-displaced carpal bone fractures with intact joint surface, conservative treatment involving immobilization for 4-6 weeks is preferred.

3.3. Distal radioulnar joint (DRUJ) injuries

They are usually associated with distal radius fractures. The difficulty in the diagnosis and treatment results from the anatomical incongruence of the joint. Indeed, DRUJ is a diartrodial joint and located between the head of the ulna and the sigmoid notch of the radius. Thus, the forearm is capable of pronation and supination. During this motion, the radius rotates around the stable ulna. The stability is provided by triangular fibrocartilage complex (TFCC) (12,13). DRUJ dorsal dislocation results from a fall onto hand with the forearm in hyperpronation and the wrist in extension, while DRUJ volar dislocation results from forced supination and direct trauma to the ulna. The most common one is dorsal dislocation (14). The primary complaint after this injury is pain. Volar dislocation limits pronation, while dorsal dislocation limits supination. In chronic cases, DRUJ may cause pain and popping sound with movement. Examination of both wrists is important. If there is pain with forced supination and volar translation of the wrist after the DRUJ is stabilized, there is ulnacarpal instability (12). In the radiologic evaluation,

anteroposterior graphy may show extension of the DRUJ, fracture of the ulnar styloid protrusion, fracture of sigmoid notch, and radial shortening. The lateral graphy may show the ulna tilting in a volar or dorsal direction. The best evaluation is performed by CT showing the relationship of the bones with each other. In ulnocarpal instability, examination under fluoroscopy may be performed (12-14); artrography shows the instability and TFCC tears. MRI and MR artrography are also useful for diagnosis. In some cases, arthroscopy is performed for diagnosis (14). If the instability is not excessive, splints can be used in the treatment. The wrist is strengthened by early physical therapy, and nonsteroid drugs may be used. In the case of a complete dislocation, if it is stable, a closed reduction is performed and the patient is immobilized in a long arm cast in neutral position and followed for 3-4 weeks (13). In the case of instable dislocation, arthroscopic or open TFCC repair is performed. In cases with non-complete but instable dislocation, rehabilitation with splinting may be initiated (12). In case of dislocations, rotational movements are allowed at week 4, then strengthening exercises are initiated (14). Despite all the treatment, there may be loss in the wrist movements and the forearm rotation (15).

3.4. Carpal instabilities

Carpal instability is defined as pain and loss of function of the joint as a result of altered anatomy and biomechanics of the wrist due to damage to the ligaments between the carpal bones (16,17). Recently, carpal instabilities have become more prominent with the observation of pain and loss of function without fractures, especially after sports injuries. The estimated incidence of heterogeneous hand and wrist injuries among all sports injuries is between 3% and 9%. Carpal bone fractures, fracture-dislocation, ligament injuries result in carpal instability for both acute and chronic overuse syndromes. Thus, the diagnosis and treatment of carpal

instabilities is of great importance for the athletes' future career (18). Furthermore, the resulting anatomical and biomechanical impairment was shown to cause severe degenerative arthritis of the wrist (19). It occurs as a result of a fall on the palm with the wrist in extension. There is pain, weakness and loss of movement in the wrist (13). In scapholunate ligament injuries, there is pain in the scapholunate region. Ecchymosis, swelling and deformity may be seen. Crepitation or clicking may be elicited. Lunotriquetral ligament injury occurs after falling on the palm. The ulnar side of the wrist is painful. There is pain with deep palpation, popping sound when the wrist is forced to the ulnar deviation, pain in the triquetrum ballotman test and pain when the ulnar side is compressed (13). Radiographs are primarily used for radiological diagnosis; however, the examination may be performed under fluoroscopy. Also, artrography, MR artrography or sometimes ultrasonography may be used. In case of suspected fracture, CT may be performed (14). However, diagnostic arthroscopy is the best diagnosis method (20). In fact, carpal instability is difficult to diagnose, which requires experience. In case of dynamic instability, conservative treatment is administered for 6-12 weeks. The conservative treatment includes splinting, nonsteroid anti-inflammatory drugs, intraarticular steroid injection, restriction of wrist movements, flexor karpi radialis proprioception training (21). Static or severe dynamic instabilities require surgical treatment.

3.5. Metacarpophalangeal joint ligament injuries

Metacarpophalangeal joint ligament injuries are commonly seen in the thumb. The ulnar collateral ligament (UCL) of the thumb may be injured acutely due to a trauma (skier's thumb) or chronically due to overuse (goalkeeper's finger). It is usually injured due to hyperextension and hyperabduction of the thumb. For a healthy hand grip strength, the ulnar collateral ligament of the thumb should be intact. In examination, the

thumb being instable when it is flexed to 30-degree indicates an UCL damage, while the thumb being instable when it is in neutral position indicates an UCL damage and a volar plaque damage. Partial injuries can be treated by splinting. About 85% of UCL injuries consist of stener lesions. A stener lesion occurs when the UCL is displaced away from its attachment onto the aponeurosis. In cases with this lesion, the UCL cannot properly heal and should be repaired by surgical treatment (22). Isolated radial collateral ligament injuries may occur as a result of forcing the thumb into flexion-ulnar deviation. They can be usually treated by non-surgical methods. High-grade or complete tears are associated with MCP subluxation and can be treated surgically (23).

3.6. Mallet finger injuries

Mallet finger is a finger deformity arising from a rupture of the terminal extensor tendon due to damage to the distal interphalangeal (DIP) joint. These ruptures may be tendinous or bony (24). Mallet finger injuries are commonly seen in working environments or sports accidents. It is common in middle-age men and most commonly seen in 3rd, 4th and 5th fingers of the dominant hand. Clinical findings of mallet finger injury included pain, edema and active extension loss at the end of the injured finger. Passive extension loss is often a sign of chronic injury. Due to swan-neck deformity secondary to this, hyperextension posture of the proximal interphalangeal joint may be seen. Radiography images usually show a portion of the bone is avulsed from the distal phalanx (bony mallet finger) (25). Conservative, non-surgical methods are usually used to treat mallet finger. The most common one among them is splints which will hold the DIP joint in extension (26). Hyperextension should be avoided because it may cause dorsal skin damage. The splint is worn continuously for 6 weeks and then it is worn only at night or during challenging activities for a further 6 weeks. A mallet finger fracture is always almost treated by non-

surgical methods if there is no volar subluxation of the joint (27). The surgical treatment indications include open injury, a large dorsal piece rupture involving more than 30% of the joint surface and palmar subluxation of the DIP (28-31).

3.7. Metacarpal fractures

Metacarpal fractures are among the most common injuries of the upper extremity. They account for about 40% of all hand fractures. They are most commonly encountered in middle-age male population. Metacarpal fractures include head, neck and diaphysis fractures. The most common metacarpal fracture is the 5th metacarpal neck fracture. Metacarpal neck fractures usually occur as a result of punching. Metacarpal fractures may be accompanied by soft tissue damage, tendon injuries, neurovascular damage, compartment syndrome etc. (32). Metacarpal injuries typically arise from an axial load and a direct trauma. Carpometacarpal base fractures arise from an axial load with the wrist in extension position. High-energy injuries such as traffic accident may result in multiple metacarpal fractures (33). With the deformation force effect of the palmar and interosseous muscles of the hand, the metacarpal fracture typically is flexed. Radiographs are used for imaging (34) (Figure 2). In cases where direct radiography is insufficient, CT should be considered for fractures around the joint and complex metacarpal fractures.

The treatment is planned according to in which metacarpus and at which grade the fracture is, as well as angulation, rotation and shortness of the fracture. Acceptable angulation values vary by the region of the fracture (32,35). Bone shortening associated with metacarpal fractures affects the extensor function. The resulting rotation causes dysfunction of the fingers. Thus, rotational deformity is an unacceptable condition, which should be corrected. If the fracture is stable without rotational deformity and

angulation and shortening are acceptable, then closed reduction and immobilization with cast and splint are usually sufficient. Surgical treatment is suitable in cases where closed reduction cannot be achieved, open fractures, intra-articular fractures, rotational deformity, angulation and shortening above acceptable limits, multiple fractures, and complicated traumas accompanied by severe soft tissue loss (36). In conservative treatment, long-term immobilization should be avoided to prevent movement restriction at the fingers. In surgical treatment, early mobilization is important in post-operative period.

References:

1. Soreide E, Hauugstvedt JR, Husby T. Arthroscopic assisted resection of triangular fibrocartilage compex lesion: A 19 years follow-up. Hand (NY) 2018;13(3):325-30.

2. Elliot SM, C Max H, Thomas GH. Characterizing the Anatomy of Uninjured Wirst. Orthopedics 2014;p:157-60.

3. S. Terry C, James H. Beaty. Campbell's Operative Orthopaedics. Philadelphia: Elsevier; 2015.

4. Adams J. Emergency medicine. Philadelphia, Elsevier; 2006.

5. Fraysse F, Costi JJ, Stanley RM, Ding B, McGuire D, et al. Novel method to replicate the kinematics of the corpususing a six degree of freedom robot. 2014;47(5):1091-8.

6. Carelsen B, Jonges R, Strackee SD, Maas M, vanKemenade P, et al. Detection of in vivodynamic 3-D motionpatterns in the wrist joint. IEEE trans Biomed Eng. 2008;56(4):1236-44.

7. Komura S, Yokoi T, Nonomura H, Tanahashi H, Satake T, et al. Incidence and characteristics of carpal fractures occurring concurrently with distal radius fractures. J Hand Surg Am 2012;37(3):469–76.

8. Geissler WB, Slade JF. Fractures of the carpal bones. In: Wolfe SW, Hotchkiss RN, Pederson WC, Kozin SH, editors. Green's Operative Hand Surgery. 6th ed. Philadelphia: Churchill Livingstone Elsevier 2011;p:639-707.

9. Özdemir G, Uçar BY, Çerçi MH, Yılmaz B, Başarır K. Isolated Triquetrum Fractures: The Importance of Proper Roentgenograms in Ulnar Sided Wrist Pain. Open Journal of Orthopedics 2015;5(07):86-188.

10. Gaebler C, McQuenn MM. Carpus fractures and dislocations. In: Bucholz RW, Court-Brown CM, Heckman JD, Tornetta P, editors. Rockwood and Green's Fractures in Adults. 7th ed. Philadelphia, Pa: Lippincott Williams &Wilkins 2010;p:781–828.

11. Al Rashid M, Rasoli S, Khan WS. Non-union of isolated displaced triquetral body fracture-a case report. Ortop Traumatol Rehabil 2012;14(1):71-4.

12. Dy CJ, Ouellette EA, Makowski AL, Extra-articular reconstructive techniques for the distal radoulnar and ulnocarpal joints. Ed. Hunt TR, Wiesel SW. Wolters Kluwer-Lippincott Williams-Wilkins. Philadelphia. 2011;p:443-451.

13. Calfee RP,Berger R, Beredjiklian PK, Engels D R, Greenberg JA, et al. Kırıklar ve çıkıklar: El bileği, ASSH EL Cerrahisi cep kitabı. Ed: Hammet WC, Calfee RP, Bozentke DJ, Boyer MI. Çeviri Ed: Yücetürk A, Mersa B, Bilgin SS, Güneş Tıp Kitappevleri. Ankara. 2014;p:216-55

14. Yücetürk A, Futbol Hekimliği, Ed: Taşer ÖF, Bayraktar B Nobel Tıp Kitabevleri İstanbul 2020;10:772-4.

15. Richards SR, Roth JH, Common wrist injuries. Sports injuries of the hand and upper extremity. Hand and upper extremity 12th Ed.Chan KM, Churchill Livingstone. New York 1995;p.213-26.

16. Özdemir G, Akgül T, Çiçekli Ö, Yılmaz B, Atbinici H, Yücel F. Lunatum excision and scaphocapitate arthrodesis in Kienböck's disease. Journal of Orthopaedic Surgery 2017 Jan;25(1):230949901769270.

17. Kilinc BE, Kara A, Sonmez MM, Oc Y, Camur S. Isolated carpal dislocation of the trapezium. Ser J Exp Clin Res; 2015;16 (1): 51-54.

18. Kara A, Celik H, Seker A, Kilinc BE, Camur S, Uzun M. Surgical treatment of dorsal perilunate fracture-dislocations and prognostic factors. International Journal of Surgery. 2015;24, 57-63.

19. Pilný J, Svarc A, Hoza P, Vodicka Z, Krbec M. Arthritis development following untreated scapholunate instability of the wrist. Acta Chir Orthop Traumatol Cech 2010;77:131-33.

20. Meyers AM, Payatakes AH, Soteranos DG. Open scapholunate ligament repair and augmentation. Ed. Hunt TR, Wiesel SW Wolters Kluwer-Lippincott Williams-Wilkins. Philadelphia. 2011;375-9.

21. Payatakes AH, Meyers AM, Sotereanos DG, Arthroscopic evaluation and treatment of scapholunate and lunotriquetral ligament disruptions. Ed. Hunt TR, Wiesel SW Wolters Kluwer-Lippincott Williams-Wilkins Philadelphia. 2011;367-74.

22. S Patel, A Potty EJ Taylor. Collateral ligament injuries of the metacarpophalangeal joint of the thumb: a treatment algorithm. Strat Traum Limb Recon 2010;5:1-10.

23. MD Miller, SR Thompson. Millers Review of Orthopaedics Seventh Edition. 2016;7:576-648.

24. Ay S, Akinci M, Ercetin O. The Brooks and Graner procedure for treatment of chronic tendinous mallet finger deformity. Tech Hand Up Extrem Surg 2004;8:21-4.

25. Wehbé MA, Schneider LH. Malletfractures. J Bone Joint Surg Am 1984;66(5):658-69.

26. Kalainov DM, Hoepfner PE, Hartigan BJ, Carroll C 4th, Genuario J. Nonsurgical treatment of closed mallet finger fractures. J Hand Surg Am 2005;30(3):580-6.

27. Ay, Ş. Tendon injuries of the hand in athletes. Türk Ortopedi Ve Travmatoloji Birliği Derneği Dergisi, 2012;11(3):201-13.

28. McCarten GM, Bennett CS, Marshall DR. Treatment of mallet thumb. Aust N Z J Surg 1986;56:285-6.

29. Lin JS, Samora JB. Surgical and Nonsurgical Management of Mallet Finger: A Systematic Review. The Journal of Hand Surgery2018;43(2):146-63.

30. Lamaris GA, Matthew MK. The Diagnosis and Management of Mallet Finger Injuries. HAND, 2016;12(3):223-9.

31. Reiter A, Hasan M, Unglaub F, Dreyhaupt J, Hahn, P. Ergebnisse der konservativen Therapie bei frischen und alten ligamentären Mallet-Finger. Der Unfallchirurg, 2005;108(12):1044-8.

32. Ashkenaze DM, Ruby LK. Metacarpal fractures and dislocations. Orthop Clin North Am 1992;23(1):19-33.

33. Friedrich JB, Vedder NB. An evidence-based approach to metacarpal fractures. Plast Reconstr Surg 2010;126(6):2205-9.

34. Brewerton DA. A tangential radiographic projection for demonstrating involvement of metacarpal heads in rheumatoid arthritis. Br J Radiol 1967;40(471):233-4.

35. Henry MH. Fractures and dislocation of the hand. In: Bucolz RW, Heckman JD, Court-Brown C, editors. Rockwood and Green's Fractures in Adults. 6th ed. Philadelphia, Pa.: Lippincolt Williams &Wilkins 2005;p:771-855.

36. Light TR, Bednar MS. Management of intra-articular fractures of the metacarpophalangeal joint. Hand Clin 1994;10(2):303-14.

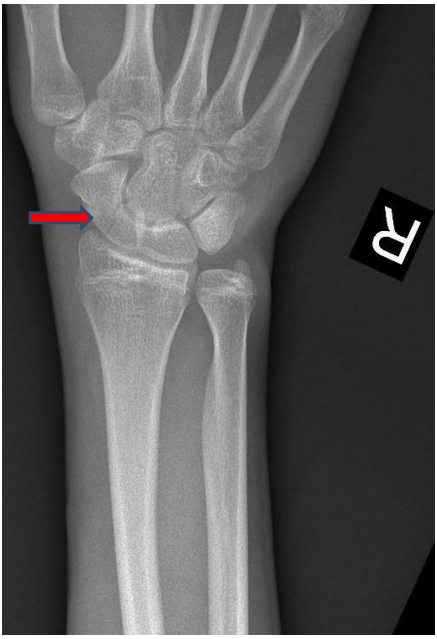

Figure 1. Anteroposterior roentgenography: Scaphoid bone fracture (red arrow).

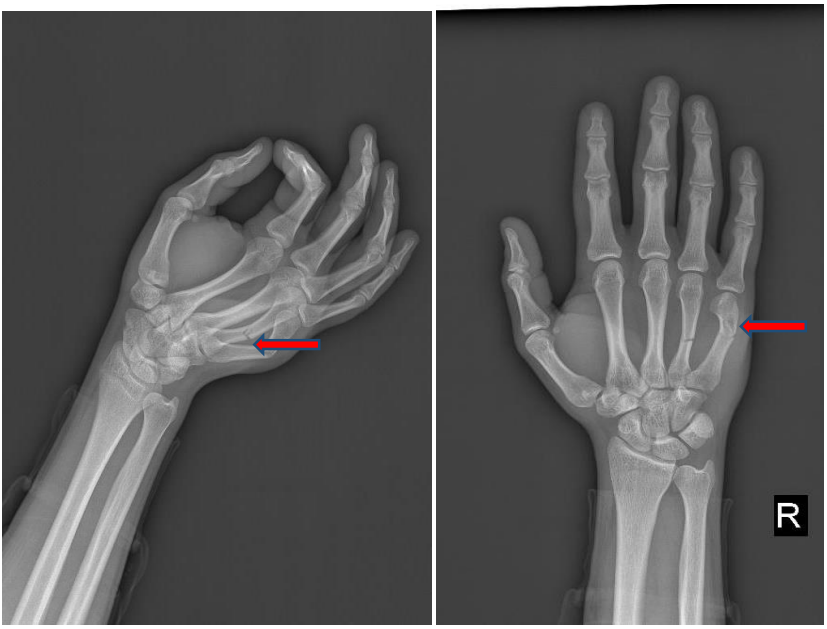

Figure 2. Roentgenography: 4th and 5th metacarpal fractures (red arrow).

II. LOWER EXTREMITY PROBLEMS IN ATHLETES

1.HIP JOINT

Semih Ak, MD

University of Health Sciences, Fatih Sultan Mehmet Training and Research Hospital, Department of Orthopaedic Surgery and Traumatology, Istanbul-Turkey

Esin Derin Çiçek, MD

University of Health Sciences, Fatih Sultan Mehmet Training and Research Hospital, Department of Radiology, Istanbul-Turkey

Ethem Aytaç Yazar, MD

University of Health Sciences, Fatih Sultan Mehmet Training and Research Hospital, Department of Orthopaedic Surgery and Traumatology, Istanbul-Turkey

1.1. Introduction

The hip joint is a ball-and-socket synovial joint, formed by the head of the femur and the acetabulum. The function of the hip joint is to transfer the load from the axial skeleton to the lower extremities and to provide a dynamic balance during movement. The joint is mainly stabilized by osseous structures. The spherical femoral head is in perfect congruence with the surface of the acetabulum forming 2/3 of a sphere. Stability is mainly provided by this harmony. The transverse acetabular ligament covering the acetabulum inferior surface increases the spherical surface, contributing to the stability. The labrum increases the depth of the joint surface and the negative intra-articular pressure, influencing the stability. The joint capsule and the ligamentum teres are other structures that increase stability (1-4).

The hip joint can be flexed to 120 degrees and extended to 15 degrees in sagittal plane. The hip flexion is fairly dependent on the position of knee joint. When the knee is at flexion position, the hip flexion may be greater, however when the knee is extended, the maximum knee flexion

degree decreases. This is associated with the increased tension of the harmstring group muscles while the knee is at extension position. Similarly, the hip may perform internal rotation of 70 degrees and external rotation of 90 degrees at the flexion position; however, these degrees decrease at the extension position. A normal hip joint allows for adduction to 30 degrees and abduction to 45 degrees. The primary restraints to these movement degrees are the capsule and soft tissues. However, the primary restraint is the bone when the congruity between the femoral head and the acetabulum is impaired in cases such as osteoarthritis, femoroacetabular impingement. The forces acting on the hip joint are often calculated statically while standing on one leg. Meanwhile, abductor force plays an important role in the ability to keep the pelvis parallel to the ground. There is a balance between the body weight and the gravitational force, as well as the joint reaction force and the abductor force (5-7).

The hip pain is common in athletes. It may be due to intra-articular or extra-articular pathologies. The most common reasons of hip pain include spine, sciatic nerve and sacroiliac joint-related pathologies. A systematic and comprehensive hip examination is very important (8). The first step in radiological evaluation is anterior-posterior radiography. The role of computerized tomography (CT) is limited for the evaluation of the hip joint. CT may be used for the evaluation of osteoid osteoma and in the presence of suspected osteochondral fragment in post-traumatic cases. Magnetic resonance imaging (MRI) provides significant information for the evaluation of acetabular labrum and periarticular soft tissues, hip joint cartilage, periarticular synovial cyst and bursitis (9-12).

1.2.Soft tissue injuries

Soft tissue injuries may involve bursal tissues, muscle groups and tendons.

Bursal Tissue Pathologies Around the Hip Joint

Bursa is the connective tissue that helps reduce friction during the movement of tendons and muscles over bone. It contains a liquid-filled pouch. The hip joint is rich in bursal tissues. Iliopsoas bursa, ischial bursa, trochanteric bursa are important bursal structures around the hip. Inflammation of bursal tissues following repetitive motions and trauma is called bursitis (11,12).

- **Trochanteric bursitis:** It may occur as a result of a trauma or excessive use of the local muscles. The patient experiences pain when the trochanter major is palpated during the physical examination. The pain is severe especially when palpating the posterior trochanter. The pain gets worse with hip abduction and external rotation against resistance.
- **Ischial bursitis:** It may occur as a result of trauma, sudden jumping movement as well as repetitive micro-traumas associated with running, cycling. The pain is localized around the ischial tuberosity at the back part of the hip, and becomes severe when sitting down. In physical examination, the palpation of the ischial tuberosity is painful. The pain gets worse when the hip is flexed and the harmstring group muscles are stretched.
- **Iliopsoas bursitis:** The iliopsoas bursa is located in the muscle-tendon junction of the psoas muscle. It is the largest bursa in the body. Iliopsoas bursitis may develop as a result of overuse, rheumatoid arthritis and acute trauma. It may occur due to exercises that involve excessive jumping, climbing stairs and

slopes. The patient may describe swelling and pain in the front of the groin area. In the physical examination site, the palpation of the groin is painful. The pain may get worse when the hip is flexed.

Radiography is usually normal in bursitis. Ultrasonography (USG) and MRI show increased fluid within the bursa. The first-line treatment includes cold application, resting, non-steroid anti-inflammatory medication. Corticosteroid may be injected into the bursa in cases that are not responsive to medical treatment. In resistant cases, the bursa is surgically excised.

Muscle and Tendon Injuries Around the Hip Joint

- **Rectus femoris strain and/or tendon rupture:** The rectus femoris muscle extends from the anteroinferior iliac spine to the tibial tuberosity. It is prone to injury since it crosses both the joints. It is usually injured as a result of powerful contraction during certain movements such as shooting, suddenly starting to run. The degree of injury is variable. In the 1st degree injuries, the clinical manifestations are mild, while (total rupture) muscle integrity is impaired in the 3rd degree injuries. The injuries may be either acute and chronic. The proximal region of the muscle is affected in acute injuries, while the distal region of the muscle is more affected in chronic injuries. The patient may describe pain in the front side of the thigh, hip and knee. The pain gets worse with hip flexion and knee extension against resistance. An avulsion fracture of the anterior inferior iliac spine may be seen on radiography.
- **Adductor Tendonitis:** It usually occurs as a result of repetitive traumas. The inflammation causes impairment of the tendon structure and thus pain. The pain is usually caused by the adductor longus tendon. The patient may describe pain that radiates from

the inner side of the groin to the inner side of the thigh. In physical examination, pain occurs with palpation over the pubic. The pain gets worse with adduction against resistance.

- **Iliopsoas Tendinopathy:** It is the inflammation that occurs in the region where the tendon is attached to the trochanter minor. It may happendue to movements with repetitive hip flexion such as climbing stairs, running uphill. Patients report anterior hip pain and groin pain. The pain gets worse with hip flexion against resistance.
- **Harmstring strain/rupture:** Hamstringis prone to injury since it crosses the hip joint and the knee joint. The injury usually involves the proximal muscle. Injury may occur during hip extension and knee flexion. The patient experiences severe pain in the back of the thigh. The pain gets worse with knee flexion against resistance.

Conventional radiographs are usually normal in all the tendon injuries. Rarely, calcification may be seen on the tendon. MRI may be used to determine the degree of injury. In general, conservative treatment is administered and the first-line treatment includes cold application, elevation, resting and NSAIDs. Physical therapy and rehabilitation is useful following the acute period. Steroid injection and surgical treatment may be applied in cases that are not responsive to treatment (13-16).

1.3. Neurological hip impingement syndromes

All of these syndromes are common in athletes. Muscle mass increases as a result of overstraining or strengthening, especially those around the hip, applying pressure on the surrounding nerve structures and hence causing these impingement syndromes (17-20).

Sciatic Nerve Entrapment

Sciatic nerve originates from L3-L4. It leaves the pelvis below the piriformis muscle and reaches the gluteal area. Sciatic nerve entrapment may result from edema, hypertrophy and hematoma in the muscles around the sciatic nerve. Sciatic nerve entrapment may occur due to repetitive movements such as jumping, climbing stairs as well as acute traumas. The chief complaint of the patient is pain radiating from the back of the hip to the leg. The pain may get worse when sitting down and squatting. In physical examination, there is tenderness at gluteal region with palpation. The pain gets worse with hip external rotation and abduction movements involving the active use of the priformis muscle.

Obturator Nerve Entrapment

The obturator nerve arises from the fusion of the branches from L2-L3-L4 nerves. It travels along the medial border of the psoas muscle. It enters the obturator foramen after travelling along the pelvic wall. Then, it divides into the motor branch and the sensation branch. The sensation branch innervates the medial thigh. The motor branch is the motor nerve of adductor muscles. It is usually entrapped inside the obturator foramen. Entrapment may occur due to hematoma or hernia. There is pain the groin and the inner thigh. It may be accompanied by numbness in these regions. Motor power loss is not common.

Genitofemoral Nerve Entrapment

Genitofemoral Nerve originates from L1 and L2 nerves. It passes through the iliopsoas muscle. It divides into genital and femoral branches at the inguinal ligament level. It is usually entrapped in hernias. Entrapment may occur following abdominal surgeries. The patient presents with the complaint of groin pain and numbness in the front side of the thigh. Hernia and hypoesthesia may be detected in physical examination.

İlioinguinal Nerve Entrapment

İlioinguinal Nerve arises from the fusion of T12 and L1 roots. It travels over the iliac bone and the pubic. It gives branches to the genital organs and the thigh inner surface. The chief complaint is groin pain. Numbness, tingling may occur in the proximal inner surface of the thigh. In physical examination, inguinal canal palpation produces pain.

Lateral Femoral Cutaneous Nerve Entrapment (Meralgia Parestetika):

It is common in athletes and those who are sitting for prolonged periods. It arises from the fusion of L2-L3-L4 nerve roots. It takes the sensation from the lateral thigh shadow. In many cases, entrapment is at the inguinal ligament level. The patient presents with the complaint of numbness in the front and side of the thigh (21)..

The most important auxiliary examinations are EMG (electromyography) and MRI for nerve entrapments. The first-line treatment is conservative treatment. Sitting for prolonged time and using tight wear such as belt should be avoided. Activity modification, cold application, NSAIDs and tricyclic antidepressants are used. Physical treatment modalities may be tried. USG-guided corticosteroid injection may be administered to resistant cases, or the nerve may be releasedsurgically in cases that do not response to treatment for 12 months.

1.4. Femoroacetabular impingement syndrome

Femoroacetabular impingement syndrome is a disease characterized by restricted joint movements, pain in the last stages of movement, due to structural abnormalities of the acetabulum or the femur. The structural bone abnormalities include “cam-type” deformity of the femoral neck, the “pincer-type” deformity of the acetabulum and the

“combined” deformity including both deformity types. In these types of the disease, the congruity between the femoral head and the acetabulum is impaired. This accelerates the degeneration, resulting in early on-set osteoarthritis. If the process is prolonged, labral tears may occur. The chief complaint of the patients is pain in the front and side of the hip. The pain gets worse with certain activities such as sitting down, squat, climbing up. In physical examination, a reduction in the range of motion of the joint may be noted. The pain gets worse with the hip internal rotation and flexion (22,23).

Radiography is very useful for diagnosis. Cam-type and pincer-type lesions can be seen in radiography. In the studies performed, for diagnosis of femoroacetabular impingement, the anteroposterior radiography of the pelvis and 45-degree Dunn radiography have been recommended as the preliminary assessment, and it was reported that MRI may be used where necessary, such as labral tears and intraarticular pathologies (24) (Figure 1).

The primary treatment includes weight loss, daily life activity modification and NSAIDs. Physical therapy modalities may be used. In treatment-resistant cases, surgical treatment may be administered to patients with labral tears, apparent osteoarthritis (24).

1.5. Intra-articular pathologies

Labral tears

The labrum is a soft tissue structure that increases the depth of the hip joint and contributes to the intra-articular negative pressure. Labral tear is the most common intra-articular hip pathology. It results from trauma, osteoarthritis and femoroacetabular impingement. Athletes usually suffer from labral damage associated with repetitive microtraumas. The chief complaint of the patient is pain radiating from the front side of the hip to

the groin area. The pain gets worse with sudden movements. The patient may describe a feeling like locking up. The pain gets worse with runs and long walks. Anterior and posterior impingement test may be used for the diagnosis. To perform the anterior impingement test, the patient is placed in the prone position, and the hip is internally rotated with adduction while the knee and the hip are flexed to 90 degrees. If the pain gets worse, the test is considered positive. To perform the posterior impingement test, the patient is placed in the supine position, and the hip is externally rotated with abduction while the knee and the hip are extended. If the pain gets worse, the test is considered positive. Radiographs do not show labral tears, but they can yield possible underlying pathologies.MRI provides valuable information in diagnosis.The first-line treatment includes conservative practices such as activity restriction, NSAIDs, physical therapy. Surgical treatment should be considered for non-responsive cases (26,27).

Intra-Articular Loose Bodies

Intra-articular loose bodies are the most common osteochondral fragments after hip dislocations. These bodies damage the cartilage surface of the femoral head and acetabulum. If the process is prolonged, degeneration and osteoarthritis may develop. X-ray, CT and MRI may be used for diagnosis. It is recommended to remove intra-articular loose bodies (if any) immediately (28,29).

1.6. Bone-related pathologies

Avascular Necrosis of the Femoral Head (ANFH)

It results from a bone-marrow pressure increase following trauma, steroid use, hemostatic diseases. Increased bone-marrow pressure leads to reduced blood flow to the femoral head. The reduction in blood flow causes cell death and necrosis. This is followed bydeformation and collapse of the joint surface. It is more common in people ages 20 to 50 years. Athletes

engaged in intense training, those suffered severe or continuous micro-trauma to the hip region, and those using steroid are at higher risk. The disease initially proceeds without symptom. The earliest symptom is usually activity-related hip pain. The risk factors should be questioned in case of suspected ANFH. MRI and scintigraphy may be used for diagnosis. The primary purpose of the treatment is to stop the progression of the disease. Anticoagulants and bisphosphonates may be used in early stage of the medical treatment. In this stage, hyperbaric oxygen therapy may be also useful. Surgical treatment is applied if the patient does not response to conservative methods (30-32) (Figure 2).

Osteitis pubis

It is an inflammation around the symphysis pubis due to overuse. The inflammatory process causes deformation of symphysis pubis bone structure, and periosteal reaction. The chief complaint of the patients is groin pain. The pain may get worse when walking and sitting up and down. There is tenderness at symphysis pubis with palpation. The pain gets worse with hip adduction. The diagnosis is confirmed by administering local anesthetic to this region. X-ray is usually normal in early stages. The gold standard in diagnosis is MRI. The primary treatment includes physical therapy practices, resting and NSAIDs. Local corticosteroid, PRP and deep massage may be administered when the conservative methods fail. Surgical treatment should be considered for resistant cases (33).

Stress Fractures

They usually result from micro fractures in the bone structure following repetitive traumas. It is more common in amateur athletes. Stress fractures in the hip region usually occur around the femoral neck and the symphysis pubis. The complaints emerge over time. The primary complaint is groin pain. The pain gets worse with activity and relieves with

resting. There is no radiological finding in early stage. MRI is usually used for diagnosis. The bone-marrow edema appearance seen on MRI is a diagnostic indicator. In case of doubt, early scintigraphy is very sensitive in detecting bone-marrow edema. The treatment may include resting, calcium and vitamin-D supplement and NSAIDs. Where necessary, physical therapy modalities may be used (34,35).

References:

1. Nho S.J., Leunig M., Kelly B.T., Bedi A., Larson C. (eds) Hip Arthroscopy and Hip Joint Preservation Surgery. 1st Ed. Thorp L.E. Hip Anatomy. Springer, New York, NY. 2014;p.3-15.

2. Glenister R, Sharma S. Anatomy, Bony Pelvis and Lower Limb, Hip. [Updated 2018 Dec 13]. In: StatPearls [Internet]. Treasure Island (FL): StatPearls Publishing; 2020.

3. Chang CY, Huang AJ. MR imaging of normal hip anatomy. Magn Reson Imaging Clin N Am. 2013 Feb;21(1):1-19.

4. Zeng WN, Wang FY, Chen C, Zhang Y, Gong XY, Zhou K, et al. Investigation of association between hip morphology and prevalence of osteoarthritis. Sci Rep. 2016 Mar;6:23477.

5. Bowman KF, Fox J, Sekiya JK. A clinically relevant review of hip biomechanics. Arthroscopy. 2010 Aug;26(8):1118-29.

6. Frankel V.H., Pugh J.W. Biomechanics of the Hip. In: Tronzo R.G. (eds) Surgery of the Hip Joint. Springer, New York, NY. 1984;p.115-31.

7. Martin HD, Shears SA, Palmer IJ. Evaluation of the hip. Sports Med Arthrosc Rev. 2010 Jun;18(2):63-75.

8. Plante M, Wallace R, Busconi BD. Clinical diagnosis of hip pain. Clin Sports Med. 2011 Apr;30(2):225-38.

9. Proenca AL, Caetano AP, Bogalho L, Adult hip radiography lines and angles, European Society of Musculoskeletal Radiology 2017 Congress, doi:10.1594/essr-2017/P-0209.

10. Polesello GC, Nakao TS, de Queiroz MC, Daniachi D, Ricioli W, Guimarães RP, et al. Proposal for standardization of radiographic studies on the hip and pelvis. Rev Bras Ortop. 2011 Nov-Dec;46(6):634-42.

11. Tagliafico A, Bignotti B, Rossi F, Sconfienza LM, Messina C, Martinoli C. Ultrasound of the Hip Joint, Soft Tissues, and Nerves. Semin Musculoskelet Radiol. 2017 Nov;21(5):582-8.

12. Jacobson JA, Khoury V, Brandon CJ. Ultrasound of the Groin: Techniques, Pathology, and Pitfalls. AJR Am J Roentgenol. 2015 Sep;205(3):513-23.

13. Lerebours FR, Cohn R, Youm T. Endoscopic Treatment of Gluteus Medius Tears: A Review. Bull Hosp Jt Dis (2013). 2016;74(1):58-62.

14. Niemuth PE, Johnson RJ, Myers MJ, Thieman TJ. Hip muscle weakness and overuse injuries in recreational runners. Clin J Sport Med. 2005 Jan;15(1):14-21.

15. Tokutake G, Kuramochi R, Murata Y, Enoki S, Koto Y, Shimizu T. The Risk Factors of Hamstring Strain Injury Induced by High-Speed Running. J Sports SciMed. 2018;17(4):650-655. Published 2018 Nov 20.

16. Nicholas SJ, Tyler TF. Adductor muscle strains in sport. Sports Med. 2002;32(5):339-44.

17. Robinson DR. Pyriformis syndrome in relation to sciatic pain. Am J Surg. 1947 Mar;73(3):355-8.

18. Gerhardt M, Christiansen J, Sherman B, Miranda A, Hutchinson W, Chahla J. Outcomes following surgical management of inguinal-related groin pain in athletes: a case series. J Hip Preserv Surg. 2020 Jan;7(1):103-8.

19. Wright R, Salisbury T, Landes J. Groin anatomy, preoperative pain, and compression neuropathy in primary inguinal hernia: What really matters. Am J Surg. 2019 May;217(5):873-7.

20. Albayrak A, Özcafer R, Balioglu MB**,** Kargin D, Atici Y, Ermis MN. Piriformis syndrome: treatment of a rare cause of posterior hip pain with fluoroscopic-guided injection. Hip International.,2015;25(2):172-175.

21. Sanjaya A. Meralgia paresthetica: finding an effectivecure. Postgrad Med. 2020;132(1):1-6.

22. Graffos A, Mohtajeb M, Mony M, Esculier JF, Cibere J, Wilson DR, et al. Biomechanics during cross-body lunging in individuals with and without painful cam and/or pincer morphology. Clin Biomech (Bristol, Avon). 2020 Jun;76:105030.

23. O'Rourke RJ, El Bitar Y. Femoroacetabular Impingement. In: StatPearls. Treasure Island (FL): StatPearls Publishing; 2020.

24. Audenaert EA, Peeters I, Vigneron L, Baelde N, Pattyn C. Hip morphological characteristics and range of internal rotation in femoroacetabular impingement. Am J Sports Med. 2012 Jun;40(6):1329-36.

25. Mascarenhas VV, Castro MO, Rego PA, et al. The Lisbon Agreement on Femoroacetabular Impingement Imaging-part 1: overview [published online ahead of print, 2020 May 14]. EurRadiol. 2020;10.1007/s00330-020-06822-9.

26. Su T, Chen GX, Yang L. Diagnosis and treatment of labral tear. Chin Med J. 2019 Jan 20;132(2):211-9.

27. Parmar R, Parvizi J. The multifaceted etiology of acetabular labral tears. Surg Technol Int. 2010;20:321-327.

28. Chernchujit B, Sanguanjit P, Arunakul M, Jitapankul C, Waitayawinyu T. Arthroscopicloose body removal after hip fracture dislocation: experiences in 7 cases. J Med Assoc Thai. 2009;92 Suppl 6:S161-S164.

29. Kargin D, Albayrak A, Atici Y, Yapici F, İlvan G, Balioglu MB. The Complication Profiles Following Surgical Dislocation of the Hip. Acta Orthop Belg. 2017;83(1):74-80.

30. Klumpp R, Trevisan C. Aseptic osteonecrosis of the hip in the adult: current evidence on conservative treatment. Clin Cases Miner Bone Metab. 2015 Jan-Apr;12(Suppl 1):39-42.

31. Hsu H, Nallamothu SV. Hip Osteonecrosis. In: StatPearls. Treasure Island (FL): StatPearls Publishing; 2020.

32. Elmalı N, Ertem K, Karakaplan M, Pepele D, Dağgez C, Topgül H. Vascular pedicled iliac bone grafting is effective in patients with an early stage of femoral head avascular necrosis. Eklem Hastalik Cerrahisi. 2014;25(1):2-7.

33. Via AG, Frizziero A, Finotti P, Oliva F, Randelli F, Maffulli N. Management of osteitis pubis in athletes: rehabilitation and return to training - a review of the most recent literature. Open Access J Sports Med. 2019;10:1-10.

34. Matcuk GR, Mahanty SR, Skalski MR, Patel DB, White EA, Gottsegen CJ. Stress fractures: pathophysiology, clinical presentation, imaging features, and treatment options. Emerg Radiol. 2016 Aug;23(4):365-75.

35. Lamothe MA, Elliott JM, Chang AH. Femoral Neck Stress Fracture in a Female Runner. J Orthop Sports Phys Ther. 2018 Apr;48(4):343.

Figure 1: Femoroacetabular impingement in anterior-posterior pelvic radiography. 1: Pincer lesion, 2: Cam lesion

Figure 2: Avascular necrosis at femoral head on plain radiography and MRI (T1-weighted coronal image).

2.KNEE JOINT

Mehmet Emin Çelebi, MD

University of Health Sciences, Fatih Sultan Mehmet Training and Research Hospital, Department of Orthopaedic Surgery and Traumatology, Istanbul-Turkey

Halil İbrahim Arıkan, MD

University of Health Sciences, Fatih Sultan Mehmet Training and Research Hospital, Department of Orthopaedic Surgery and Traumatology, Istanbul-Turkey

Barış Yılmaz. MD, Assoc. Prof.

Health Science University, Fatih Sultan Mehmet Training and Research Hospital, Department of Orthopaedic Surgery and Traumatology, Istanbul-Turkey

2.1. Introduction

The knee joint is the largest and most complicated joint in human body. Thus, it is one of the joints most prone to damage, and the incidence of knee injuries has increased day by day due to rapid increase in sports injuries (1,2). The knee joint consists of bone structures such as patella, distal femur, proximal tibia as well as ligaments and corresponding soft tissue structures. It is generally accepted that it consists of two distinct joints; the tibiofemoral and the patellofemoral joints. The tibiofemoral joint is further divided into medial and lateral compartments. This joint is considered as a hinge (ginglymus) type joint that allows for only flexion and extension movements, however it has also the capability of lateral and medial rotation under certain conditions. When the knee joint is fully extended, the connective structures are strained and any rotation movement cannot occur. However, after a 20-degree flexion, the ligaments become loosened and the knee can perform some rotation movements. At a 90-degree flexion, the ligaments loosen to the full extent and can perform approximately 40-degree rotation movement.

It is important to assess the initial walking style of the patient and how he/she puts weight to his/her extremities. This assessment will help distinguish pain on the knee reflected by the back, hip and foot. In case of clinical compliance, the patient's duck walk (walking while squatting) may provide us with general information. A patient who can do this walk is not expected to have articular conditions such as arthritis, ligament instability, meniscus tear or common effusion (3). Then, a general examination should be made to assess swelling, redness, bruising or other discoloration, varus or valgus alignment, atrophy or hypertrophy, recurvatum posture, contractures, temperature rise, pain, swelling, effusion. The skin temperature over the patella should be compared with the upper and lower skin and the other knee. The presence of sensitive points in the bone and soft tissue is extremely important. Temperature increase is a marker of inflammation.

The joint range of active and passive motion of the knee may be an important clinical sign. The normal knee extension ranges from -10 to 0 degree, and the normal knee flexion ranges from 130 to 150 degree. Comparison with the painless knee would be more useful. Muscle strength should be evaluated by forcing the knee into flexion and extension. Then, the neurological examination is completed by sensory examination and reflex examination (4). There are many tests for knee examination to show which anatomic structure(s) are injured. However, these tests are of concern to orthopeadists especially those interested in knee surgery. After taking medical history of the patient and performing physical examination, radiological examinations may be used for the suspected injured structures. Radiography should be the first-step for bone structures. Sometimes, CT may be required to examine the bone structures comprehensively. Since, like other joints, the knee joint contains complex structures such as bone, cartilage, ligament, tendon, meniscus, joint capsule and surrounding

muscles, MRI with higher sensitivity and specificity is very helpful to finalize the diagnosis and treatment when evaluating the soft tissues. USG is very rarely used for the knee joint; however, it may be used to evaluate the superficial bursa, popliteal fossa and intra-articular effusion (5).

2.2. Meniscus injuries

Meniscus is a tissue prone to injury, especially in those dealing with contact sports and non-contact sports (6,7). Although the studies have reported different rates, the meniscal tear is more common in men than women. Both lateral and medial meniscal tears usually involve the posterior horns; the anterior tears are usually the extension of the posterior ones. The diagnosed isolated tears are three times commonly in medial side than the lateral side, while in patients with acute Anterior cruciate ligament (ACL) tear, longitudinal or oblique tears are usually detected in the posterior horn of the lateral meniscus. About 1/3 of acute traumatic meniscal tears is accompanied by ACL tears.

They usually occur as a result of a serious rotational trauma; they are in the vertical plane, and in the longitudinal or oblique direction. Degenerative meniscal tears frequently occur in men after the 4th decade. Trauma history is not always available, and radial or horizontal and complex tears are more common; the meniscal tears are frequently accompanied by chondral erosion in the same side compartment; there may be extremity axle disorder (8).

The history and physical examination can lead to the diagnosis in about 70% of cases. The patients experience knee pain as well as feeling like locking up depending on the type and size of the tear. Effusion and synovial hypertrophy may be detected; it may present with patellofemoral arthritis findings. However, there may be relatively small tears which do not lead to much complaints, giving symptom occasionally. MRI is the

most commonly used method for the diagnosis of meniscal tears. Several studies reported that the accuracy rate of MRI for the diagnosis of meniscus lesions has been between 65-99% (9) (Figure 1).

2.2. Ligament injuries

Anterior cruciate ligament tears

These ligament tears, which is a problem experienced by young individuals due to sports injuries, may occur as full or partial injuries. The rate of injury is higher in female athletes than male athletes, however the rate of tears requiring surgical treatment is higher in men. These ligament tears more commonly coexist with the lateral meniscal tears. In chronic cases, there are chondral damages, and complex meniscal tears may occur. A narrow intercondylar distance due to anatomical structure also constitutes a risk for rupture. Cases with this ligament tear presents with swelling and pain in the knee in the acute stage. The expression “a sound came out from my knee” described by the patient at the time of injury is called “pop sign”. The patient states that his/her knee is swollen just afterwards. Indeed, hemarthrosis is seen in 70% of cases with acute tears. Chronic cases describe recurrent knee effusions. The knee slides forward while walking, causing the patient to feel like falling into space. This results from dysfunction of ACL which contributes to 85% of the anterior translation of the knee. The catching and locking sensation experienced by these patients indicate the presence of accompanying meniscal tears. This ligament that is one of the most prone to get damages in sports injuries cannot be self-healed when it tears, and requires surgical treatment for those who want to continue do sport actively (10-12) (Figure 2).

Posterior cruciate ligament tears

Although isolated posterior cruciate ligament (PCL) tears are well-defined, their rates are lower. Because, the magnitude of overloading that

may cause the PCL injury is higher compared with the ACL. However, injuries severe enough to cause the PCL rupture may also cause other structures of the joint to get injured. 40% of the cases have isolated injury, while 60% of them have combined injury. The most common isolated injury mechanism is the PCL ruptures that occur as a result of directly pushing the tibia back with the knee flexed to 90 degrees. Rupture occurs as a result of hitting front panel of car during a car accident or collisions with similar mechanisms during motor sports. Rarely, PCL ruptures, caused by overloading from hyperflexion, were reported. In case of suspected PCL injuries, the clinical examination should be performed taking into consideration not only PCL but also other injuries. Posterior drawer test at 90 degrees is effective for the examination of the PCL. Contrary to the ACL ruptures, surgical treatment is usually not required for the ACL ruptures. However, in case of injury of both ligaments, the PCL firstly and then the ACL should be treated surgically in the same or a subsequent operation (13).

Medial collateral ligament tears

Medial collateral ligament (MCL) injuries result from abduction strains beyond the physical limits for the knees in semiflexion and extension where the activations are realized (14). Many studies demonstrated that MCL is the primary restraint against valgus strains and the ACL plays a minor role in this regard. Instability arising from isolated sectioning of MCL indicates a gapping of 4 mm in the knee at 25°-flexion, while a gapping beyond this value indicates that the primary resistance effect of the ligament has disappeared. Because, a larger gapping observed with valgus stress in clinical examination indicates the involvement of pathologies in capsular and cruciate ligaments (15).

Posterolateral corner injuries

65% of these injuries occur during sports activities. Because, the popliteus tendon, one of the static components of posterolateral corner, prevents external rotation, varus and posterior translation. The lateral collateral ligament is the primary resistant to varus stress. However, 1.6-7% of the knee ligament injuries is accompanied by posterolateral corner injuries, depending on the severity of the injury. It most commonly coexists with the ACL injuries, and if only the ACL is repaired in these cases, the risk of failure is very high. These injuries may be also associated injuries such as knee dislocation, common peroneal nerve injury, vascular injury, avulsion fracture of the fibular head. The physical examination findings are usually sufficient for diagnosis. The posterolateral corner is painful. 25% of the cases may have dysesthesia and leg weakness due to peroneal nerve damage. Due to instability in the knee when it is fully extended, the patient holds the knee in flexion. The diagnosis is confirmed by X-ray and MRI.

Multiple ligament injuries

Traumas involving injury of two or more ligaments are called multiple ligament injuries. Treatment of this presentation resulting from high-energy traumas is complicated. Possible neurovascular injuries should be considered although the knee appears reduced in cases accompanied by knee dislocation. In case of early hemarthrosis, the case is followed up by bracing. Then, the surgical treatment is administered, usually in stages.

2.4. Osteochondral lesions

One of the reasons of anterior knee pain is chondral and osteochondral injuries of the patellofemoral joint. Of advanced stage focal cartilage injuries in the knee, 11-23% occur in the patella, 6-15% in the

femoral trochlea (16-18). The lesions may be classified as chondral, osteochondral or subchondral (19). In case of osteochondral lesions, the subchondral bone and/or the cartilage on it may be injured depending on the stage. Osteochondritis dissecans is the detachment of an osteochondral fragment from the surrounding bone and cartilage tissue. It is common in youths and athletes. The typical patient profile is male aged 15-20 years. It is generally unilateral (20). A single direct impact may cause osteochondral fracture and detachment, as well as a subchondral stress fracture may occur due to repetitive microtrauma without a certain trauma, causing the detachment of the fragment over time. In many cases, the cause of repetitive microtrauma is apparent biomechanical disorder (19,21). Cartilage damage in the patellofemoral joint following acute patella dislocations has been reported to be 95% (2). Some of the patients stated that the symptoms has emerged when lifting weight with the knees bent, while some stated that the symptoms have emerged over time (22) (Figure 3).

The chief complaint of the patients with patellofemoral cartilage damage is the pain in front of the knee. The pain may be defined as like stemming from the front, back or around the patella. (22,23). The cartilage has no nerve tissue and thus the pain is always referred pain. The actual reason underlying the pain may be irritation of synovial or capsular tissues or overloading of the subchondral bone. Movements that increase the patellofemoral contact load cause the pain to get worse. The second common complaint is catching sensation or free sensation in the knee. Swelling is not a common cause for admission (24).

In physical examination, crepitation, effusion, tenderness on the patella joint surface may be determined (25). The crepitation may be due to the underlying cartilage damage as well as interpositioned soft tissues such as fat pad, synovial plica or hypertrophic synovial tissue. The joint is

moved along the motion arch by compressing the patella by hand to determine the location of the injury. If the pain does not appear with the patellar compression, it should be suspected that the pain stems from other source than the joint surface.

Cartilage injuries are located mostly in distal and medial regions, and are almost never seen in the superior pole. The first imaging step is radiographic examination. These graphies may show degenerative alterations, trochlear dysplasia, patellar slope and partial dislocation (subluxation) or joint mouse. Osteochondritis dissecances lesion and trochlear displasia can be best seen in lateral radiography. MRI can perfectly show soft tissues discrimination, internal cartilage structure and surface impairments (18), and also provide information on the stability of osteochondral fragment inside the crater and the viability of the fragment.

2.5. Synovial lesions

Synovial osteochondromatosis is an uncommon disease characterized by cartilaginous proliferation of the synovium (26). It is of unknown etiology;however, it is thought to be caused by trauma or infection-related synovial irritation. As a result of villous, nodular cartilage metaplasia of the synovium, the cartilaginous or osteocartilaginous nodules form in the synovial membrane, bursa and tendon sheath. The formed nodules detach and become free, thus free fragments form in the joint spacing (27).

There are two types of synovial osteochondromatosis; primary and secondary. The primary type is almost always monoarticular and involves major joints. It presents the 3rd and 4th decades of life and is more common in men than women. However, the secondary type being more common presents in older ages and after pathologies such as trauma, osteoarthritis

or neuropathic arthropathy (28). It is a suspected cause of knee pain especially in veteran athletes.

2.6. Patellofemoral pathologies

Patellofemoral problems are the leading problems frequently encountered by a sports physician in clinic. It was reported that in approximately 10% of the patients who have admitted to clinics due to sports injury, the problem has been stemmed from the patellofemoral joint. The etiology of patellofemoral problems, which are also defined as an overuse injury in athletes, can be studied comprehensively (29). As is known, the patellofemoral joint is the musculoskeletal joint being subjected to maximum load in a human body. It was estimated that the patellofemoral joint is subjected to a load of 3.3 times of the body weight while climbing down stairs, 7.6 times of the body weight while squatting and 20 times of the body weight while jumping (30). The realistic treatment for patients with patellofemoral joint-related pain is possible when the pathophysiology of the problem is understood well. This is achieved only by a carefully taken medical history as well as good interpretation of the findings obtained from physical and functional assessment.

Patellar compression syndrome

Patellar compression syndromes result from substantially restricted range of motion of the patella due to stiffness or shortness of the surrounding structures. This is a syndrome seen in athletes, which is either congenital or develop following a severe injury. It generally occurs in the lateral edge of the patella, causing the involvement of the cartilage in this region.

Excessive lateral pressure syndrome may develop due to the congenital lateral tilt of the patella. Stress produced over time and with the growth of bone causes a chronic slope effect on the patella (31). The pain

usually appears while climbing up and down stairs, squatting and going downhill. The symptoms may get worse with the erosion and degeneration of cartilage tissue, and crepitation may develop with active and passive movements. Excessive chronic loading of the lateral facet causes significant loss in the patellar facet joint cartilage. The most important finding in physical examination is the lateral tilting of the patella, and the soft tissues in lateral side being more strained compared with medial side. Atrophy is frequently seen in the vastus medialis muscle of the patients. It is diagnosed radiologically (32).

Global patellar compression syndrome is another patellar compression syndrome due to the excessive shortening of both medial and lateral retinaculum. This syndrome usually develops secondary to a local trauma (with the development of fibrosis in the retinacula as a result of inflammation caused by direct impact on the patella). In prolonged immobilization, the mobility of the patellofemoral joint reduces, and adaptive shortness create in the tissues around the patella. Secondary to the patellar movement restriction, the tibiofemoral joint movement is often restricted. This demonstrates the importance of a careful and meticulous treatment in sports injuries. Standard radiological images and especially *skyline Merchant view* (superior-inferior axial projection) provide convenience for the diagnosis.

Patellar instability

Patellar instability is a subjective concept that describes pain, blockage and catching sensation in the knee as a result of the impairment of static and dynamic balance of the extensor mechanism of the knee. Patellar partial dislocation (subluxation) is defined as temporary lateral motion of the patella in the early stage of knee flexion. The lateral motion degree of the patella varies from person to person. The partial dislocation may occur due to congenital femoral deficiencies, impaired mechanical

axis of lower extremity, excessive hip anteversion, external tibial torsion, increased foot pronation, soft tissue and muscle imbalances around the patella (33-35). A connective tissue laxity may trigger extensor mechanism disorder (36).

The majority of patients have complaints of release, instability and pain. Since the partial dislocation is usually accompanied by the patellar slope, the majority of patients states that they feel discomfort and tension around the patella. Many patients describe their experiences together with a locking or catching sensation due to the partial dislocation with these words “I feel like I’m jumping over an object” or “I cannot control my knee cap”. The pain is localized to the medial edge of the patella in many cases and to the distal pole of the patella in rare cases. The patients may restrict the sport activities due to concern, lack of confidence and instability. In the physical examination with palpation, there is tenderness in the distal pole of the patella, the medial retinacular region and the distal section of the quadriceps. The patient feels restless during patellar lateral tilt test (positive Fairbanks sign).

The incidence of full dislocation (luxation) was reported to be 5.8 per 100.000 persons. This rate is approximately five times higher for the 10-17-year age group (37-39) (Figure 4). Acute patellar full dislocation suddenly occurs due to trauma or impaired lower extremity alignment (40). The patella removes from the trochlear groove in an uncontrolled manner due to the extensor mechanism deficiency and forcing the knee into valgus, flexion and external rotation as a result of a sudden stress. It is more common in sports such as soccer, ski. In direct injuries, there is patellar lateral tilt. Medial dislocations are rare and typically iatrogenic. In the literature, a superior dislocation of patella in a rugby player was reported (41). After the acute patella dislocation, the knee is swollen and may be locked due to pain and edema. There is pain on the medial retinaculum,

and sometimes tear occurs on the retinaculum. The exact location of the pain is the adductor tubercle from which the patellar ligament originates. Other ligament structures of the knee should be evaluated due to swelling, locking and pain.

Biomechanical dysfunction

Patellofemoral pain may result from various activities depending on biomechanical factors that affect the patellofemoral joint. Abnormal biomechanics may produce pain even during sport or daily activities. Length difference between two extremities, loss of flexibility in soft tissue and muscular structures, impaired foot mechanics, increased medial tibial torsion, muscular imbalance etc. may cause patellofemoral problems or pain (42). A study on young girl basketball player showed the relation between the patellofemoral pain and the increased knee abduction momentum due to a vertical fall (43). In another recent study on female athletes, strength training exercises to strengthen the hip abductor muscle group would be effective in the treatment of patellofemoral pain (44). Another similar study reported that the hip abductors have been weaker in runners with patellofemoral pain syndrome, and thus the hip adduction has got worse towards the end of the prolonged run (45). Dynamic assessment of the lower extremity biomechanics is also very important for the determination of the pathology. Foot pronation, choice of shoe, excessive kicking of heels while running or abnormal angle of hallux valgus may be associated with the patellofemoral pain (46).

Direct patellar trauma

The joint cartilage may be injured when the patella is directly subjected to trauma especially during contact sport or daily activities. A common retropatellar pain appears with movement especially in the first moment of the trauma. Contraction of the quadriceps produces pain and dysfunction. The diagnosis and treatment options should be evaluated

taking into consideration cartilage damage as well as full dislocation or fracture. It is important to distinguish radiographically the bipartite patella from the patella fractures.

Soft tissue lesions

Bursitis involving the patellofemoral joint are common. Prepatellar bursitis, which are more common in those engaging with sports such as wrestling, soccer, volleyball, ice hockey, develops as a result of direct impact to the patella or falling onto it (48). It is more common in those working in squat position. The prepatellar bursitis is very painful, sensitive and swollen in the acute stage.

The iliotibial band is a structure that plays an important role in the extensor mechanism of the knee. The distal side of the iliotibial band is thick, strengthens the lateral retinaculum, and some branches attach to the patella. Excessive shortening and tightness of the iliotibial band leads to abnormal lateral patellar movement as well as iliotibial band syndrome. It is more common in long-distance runners and bicyclers. It is more remarkable in those who are running hill due to increased friction (49). As a result of friction, inflammation, patellar dysfunction and impairment of jumping ability occur (50). The pain in the proximal tibia and lateral joint line gets worse with activity and relieves with resting.

References:

1. Sonzogni JJ. Examiningtheinjuredknee. EmergMed1996;28:76-86.

2. Stiell IG, Greenberg GH, Wells GA, McDowell I, Cwinn AA, Smith NA, et al. Prospective validation of a decision rule for the use of radiography in acute knee injuries. JAMA. 1996 Feb 28;275(8):611-5.

3. Schraeder TL, Terek RM, Smith CC. Clinical evaluation of the knee. N Engl J Med. 2010 Jul 22;363(4):e5.

4. Rossi R, Dettoni F, Bruzzone M, Cottino U, D'Elicio DG, Bonasia DE. Clinical examination of the knee: know your tools for diagnosis of knee injuries. Sports Med Arthrosc Rehabil Ther Technol. 2011 Oct 28;3:25.

5. Fulkerson JP. Diagnosis and treatment of patients with patellofemoral pain. Am J Sports Med. 2002 May-Jun;30(3):447-56.

6. Atbaşi Z, Erdem Y, Neyişçi Ç, YIlmaz B, Demiralp B. An anatomical examination of iatrogenic nerve injury during inside out meniscus repair with flexion and extension of the knee. Ulus Travma Acil Cerrahi Derg. November 2019;25(6):555-560.

7. Fox AJ, Wanivenhaus F, Burge AJ, Warren RF, Rodeo SA. The human meniscus: a review of anatomy, function, injury, and advances in treatment. Clin Anat. 2015 Mar;28(2):269-87.

8. Maffulli N, Longo UG, Campi S, Denaro V. Meniscal tears. Open Access J Sports Med. 2010 Apr 26;1:45-54.

9. Oei EH, Nikken JJ, Verstijnen AC, Ginai AZ, Myriam Hunink MG. MR imaging of the menisci and cruciate ligaments: a systematic review. Radiology. 2003 Mar;226(3):837-48.

10. Yılmaz B, Özdemir G, Keskinöz EN, Tümentemur G, Gökkuş K, Demiralp B. Comparing Dimensions of Four-Strand Hamstring Tendon Grafts with Native Anterior and Posterior Cruciate Ligaments. Biomed Res Int. 2016;2016:3795367.

11. Kilinc BE, Kara A, Camur S, Oc Y, Celik H. Isokinetic dynamometer evaluation of the effects of early thigh diameter difference on thigh muscle strength in patients undergoing anterior cruciate ligament reconstruction with hamstring tendon graft. Journal of Exerc Rehabil. 2015;1(2), 95-100.

12. Kilinc BE, Kara A, Celik H, Oc Y, Camur S. Is anterior cruciate ligament surgery technique important in rehabilitation and activity scores? Journal of Exercise Rehabilitation. 2016;12(3), 232-234.

13. Kennedy JC, Hawkins RJ, Willis RB, Danylchuck KD. Tension studies of human knee ligaments. Yield point, ultimate failure, and disruption of the cruciate and tibial collateral ligaments. J Bone Joint Surg Am. 1976 Apr;58(3):350-5.

14. Lechner CT, Dahners LE. Healing of the medial collateral ligament in unstable rat knees. Am J Sports Med. 1991 Sep-Oct;19(5):508-12.

15. Grood ES, Noyes FR, Butler DL, Suntay WJ. Ligamentous and capsular restraints preventing straight medial and lateral laxity in intact human cadaver knees. J Bone Joint Surg Am. 1981 Oct;63(8):1257-69.

16. Arøen A, Løken S, Heir S, Alvik E, Ekeland A, Granlund OG, et al. Articular cartilage lesions in 993 consecutive knee arthroscopies. Am J Sports Med. 2004 Jan-Feb;32(1):211-5.

17. Curl WW, Krome J, Gordon ES, Rushing J, Smith BP, Poehling GG. Cartilage injuries: a review of 31,516 knee arthroscopies. Arthroscopy. 1997 Aug;13(4):456-60.

18. Hjelle K, Solheim E, Strand T, Muri R, Brittberg M. Articular cartilage defects in 1,000 knee arthroscopies. Arthroscopy. 2002 Sep;18(7):730-4.

19. LLopis E, Padrón M. Anterior knee pain. Eur J Radiol. 2007 Apr;62(1):27-43.

20. De Smet AA, Fisher DR, Graf BK, Lange RH. Osteochondritis dissecans of the knee: value of MR imaging in determining lesion stability and the presence of articular cartilage defects. AJR Am J Roentgenol. 1990 Sep;155(3):549-53.

21. Nomura E, Inoue M, Kurimura M. Chondral and osteochondral injuries associated with acute patellar dislocation. Arthroscopy. 2003 Sep;19(7):717-21.

22. Gomoll AH, Minas T, Farr J, Cole BJ. Treatment of chondral defects in the patellofemoral joint. J Knee Surg. 2006 Oct;19(4):285-95.

23. Elias DA, White LM. Imaging of patellofemoral disorders. Clin Radiol. 2004 Jul;59(7):543-57.

24. Wilk KE, Davies GJ, Mangine RE, Malone TR. Patellofemoral disorders: a classification system and clinical guidelines for nonoperative rehabilitation. J Orthop Sports Phys Ther. 1998 Nov;28(5):307-22.

25. Aglietti P, Buzzi R, Insall J. Disorders of thepatellofemoraljoint. In: Insall J, Scott N, editors. Surgery of theknee. 3rd ed. Philadelphia: Churchill Livingstone; 2001. p. 913-1043.

26. Jonathan K, Schumacher HR. Miscel laneous arthropathies including synovial tumors and foreign body synovitis and nephrogenic systemic fibrosis. InHochberg MC, Silman AJ, SmolenJS, Weinblatt ME, Weisman MH, editors. Rheumatology. 5th ed. Mos by Elsevier; 2011.p.1676-88.

27. Ackerman D, Lett P, Galat DD, Parvizi J, Stuart MJ. Results of total hip and total knee arthroplasties in patients with synovial chondromatosis. J Arthroplasty. 2008 Apr;23(3):395-400.

28. Hamada J, Tamai K, Koguchi Y, Ono W, Saotome K. Case report: A rare condition of secondary synovial osteochondromatosis of the shoulder joint in a young female patient. J Shoulder Elbow Surg. 2005 Nov-Dec;14(6):653-6.

29. Stein CJ, Micheli LJ. Overuse injuries in youth sports. Phys Sportsmed. 2010 Jun;38(2):102-8.

30. Panni AS, Tartarone M, Patricola AA, Santaiti D. Patellofemoral problems. In: Volpi P, editor. Football traumatology-current concepts: from prevention to treatment. Milan: Springer; 2006. p.263-74.

31. Fulkerson JP, Tennant R, Jaivin JS, Grunnet M. Histologic evidence of retinacular nerve injury associated with patellofemoral malalignment. Clin Orthop Relat Res. 1985 Jul-Aug;(197):196-205.

32. Schutzer SF, Ramsby GR, Fulkerson JP. Computed tomographic classification of patellofemoral pain patients. Orthop Clin North Am. 1986 Apr;17(2):235-48.

33. Fitzgerald GK, McClure PW. Reliability of measurements obtained with four tests for patellofemoral alignment. Phys Ther. 1995 Feb;75(2):84-90; discussion 90-2.

34. Yılmaz B, Çiçek ED, Şirin E, Özdemir G, Karakuş Ö, Muratlı HH. A magnetic resonance imaging study of abnormalities of the patella and patellar tendon that predispose children to acute patellofemoral dislocation. Clin Imaging. 2017 Mar-Apr;42:83-7.

35. Merchant AC. Classification of patellofemoral disorders. Arthroscopy 1988;4:235-40.

36. Yılmaz B, Ozdemir G, Sirin E, Cicek ED, Anıl BS, Bulbun G. Evaluation of patella alta using MRI measurements in adolescents. Indian J Radiol Imaging. 2017 Apr-Jun;27(2):181-6.

37. Fithian DC, Paxton EW, Stone ML, Silva P, Davis DK, Elias DA, et al. Epidemiology and natural history of acute patellar dislocation. Am J Sports Med. 2004 Jul-Aug;32(5):1114-21.

38. Dorris JR, Ward KP. Patella-femoral knee instability in a college basketball player. J Med Assoc Ga. 2000 Jun;89(2):38.

39. Yılmaz B, Şirin E, Özdemir G, Çiçek ED, Karakuş Ö, Demir Aİ, Muratlı HH. Acute traumatic primary patella dislocation in children and adolescents: A detaile devaluation of theim pactupon the results. Open Journal of Orthopedics 2018;8,102-115.

40. Kurock W, Sennerich T. [Diagnosis and therapy of traumatic patellar dislocation in the athlete]. Z Kinderchir. 1987 Jun;42(3):178-80.

41. Saleemi AJ, Hussain A, Iqbal MJ, Thuse MG, George AA. Superior dislocation of patella in a rugby player: an update on a extremely rare condition and review of literature. Knee Surg Sports Traumatol Arthrosc. 2007 Sep;15(9):1112-3.

42. Kaya D, Citaker S, Kerimoglu U, Atay OA, Nyland J, Callaghan M, et al. Women with patellofemoral pain syndrome have quadriceps femoris volume and strength deficiency. Knee Surg Sports Traumatol Arthrosc. 2011 Feb;19(2):242-7.

43. Myer GD, Ford KR, Barber Foss KD, Goodman A, Ceasar A, Rauh MJ, et al. The incidence and potential pathomechanics of patellofemoral pain in female athletes. Clin Biomech (Bristol, Avon). 2010 Aug;25(7):700-7.

44. Fukuda TY, Rossetto FM, Magalhães E, Bryk FF, Lucareli PR, de Almeida Aparecida Carvalho N. Short-term effects of hip abductors and lateral rotators strengthening in females with patellofemoral pain syndrome: a randomized controlled clinical trial. J Orthop Sports Phys Ther. 2010 Nov;40(11):736-42.

45. Dierks TA, Manal KT, Hamill J, Davis IS. Proximal and distal influences on hip and knee kinematics in runners with patellofemoral pain during a prolonged run. J Orthop Sports Phys Ther. 2008 Aug;38(8):448-56.

46. Barton CJ, Bonanno D, Levinger P, Menz HB. Foot and ankle characteristics in patellofemoral pain syndrome: a case control and reliability study. J Orthop Sports Phys Ther. 2010 May;40(5):286-96.

47. Atesok K, Doral MN, Lowe J, Finsterbush A. Symptomatic bipartite patella: treatment alternatives. J Am Acad Orthop Surg. 2008 Aug;16(8):455-61.

48. Steinacker T, Verdonck AJ. [Endoscopic therapy of pre-patellar bursitis]. Sportverletz Sportschaden. 1998 Dec;12(4):162-4.

49. Ferber R, Noehren B, Hamill J, Davis IS. Competitive female runners with a history of iliotibial band syndrome demonstrate atypical hip and knee kinematics. J Orthop Sports Phys Ther. 2010 Feb;40(2):52-8.

50. Hudson Z, Darthuy E. Iliotibial band tightness and patellofemoral pain syndrome: a case-control study. Man Ther. 2009 Apr;14(2):147-51.

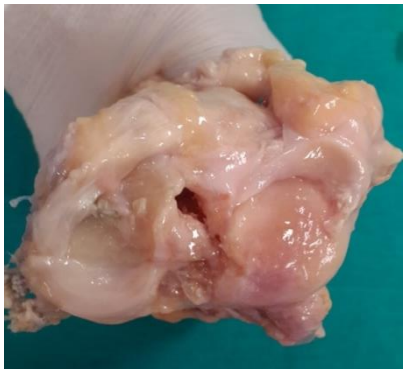

Figure 1. Medial and lateral meniscus in cadaver

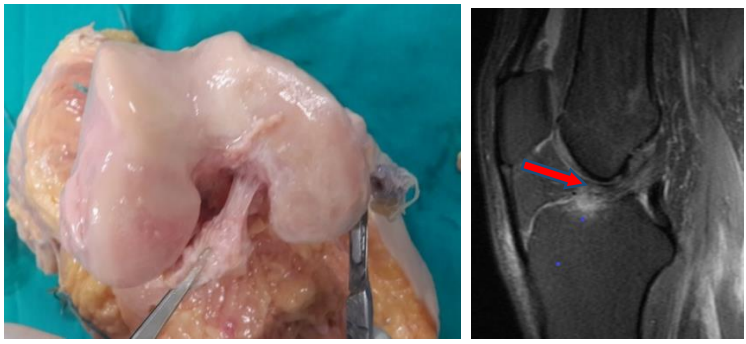

Figure 2. Anterior cruciat ligament in cadaver, and ligament rupture (MRI, sagittal plane)(red arrow).

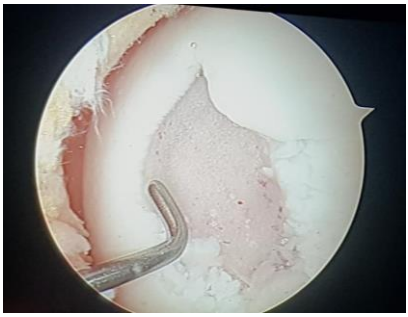

Figure 3. Osteochondritis dissecans in the knee joint (arthroscopic view)

Figure 4. Acute patellar dislocation (on the right image: MRI, axial plane) (patella, red arrow).

3. FOOT AND ANKLE JOINT

Onur Gültekin, MD

University of Health Sciences, Fatih Sultan Mehmet Training and Research Hospital, Department of Orthopaedic Surgery and Traumatology, Istanbul-Turkey

Mehmet Berke Yuşan, MD

University of Health Sciences, Fatih Sultan Mehmet Training and Research Hospital, Department of Orthopaedic Surgery and Traumatology, Istanbul-Turkey

Mustafa Hakan Özdemir, MD

University of Health Sciences, Fatih Sultan Mehmet Training and Research Hospital, Department of Orthopaedic Surgery and Traumatology, Istanbul-Turkey

3.1. Introduction

The ankle is a diartrodial joint that works like a hinge. There is a socket, namely mortise, formed by the distal end of the tibia, and the medial and lateral malleoli. The body of the talus sits within the mortise. The lateral malleolus is more posteriorly placed compared to the medial malleolus; thus the ankle joint has 18-30 degrees of external rotation with reference to the knee in the transverse plane (1,2). The foot consists of 28 bones and 32 joints. It is typically addressed in 3 regions. The forefoot consists of phalanges, the sesamoids underlying the first metatarsophalangeal joint; the midfoot consists of the medial, middle and lateral cuneiforms, as well as cuboid and navicula. The hindfoot consists of the calcaneus and talus.

The physical examination begins with the inspection of walking and the external appearance of the foot. The presence of swelling, deformity, erythema, tophus, subcutaneous nodules, and ulcers is checked

(Figure 1). The characteristic of swelling may depend on the region. For example, ankle causes diffuse swelling anteriorly, eliminating the two small depressions present typically in front of the malleoli. Ankle tenosynovitis shows as linear swelling localized to the distribution of the tendon sheath extending along the joint. Swelling in Achilles tendon region may be the result of tendon rupture, calcaneal bursitis, rheumatoid nodule or urate tophus. Intertarsal joint arthritis causes diffuse swelling on the medial and dorsal surfaces of the foot. Metatarsophalangeal joint synovitis is associated with diffuse swelling in the back of the forefoot with a potential of masking the extensor tendons. Digital flexor tenosynovitis causes a diffuse and soft swelling on the plantar surface of the toe (namely sausage toe). The subtalar joint deformities leading to the eversion (calcaneovalgus) or inversion (calcaneovarus) of the heel are best observed from the back. Equnius and calcaneus represent the plantar flexion and dorsiflexion angulation of the ankle, respectively. Inspection while the patient is standing may show the loss of the longitudinal arch (pes planus) or the increase in the arch height (pes cavus). The toes are simply the extension of the metatarsals. The presence of deformities in the toes (Hallux valgus, claw, hammer, mallet finger, etc.) is crucial for both causing wounds on the foot and for its potential of causing general injuries due to falling (3,4).

The toe movements are tested while the knee is in flexion. The normal range of motion is 15-25 degrees of dorsiflexion in the neutral position and 40-50 degrees of plantar flexion. A painful and tender heel can have several reasons. In plantar fasciitis, there is tenderness without swelling in the site where the plantar fascia attaches to the inferomedial surface of the calcaneus. In the painful calcaneal fat pad (painful heel pad syndrome), a local tenderness is present in the center of the heel. Subcalcaneal bursitis causes a tender swelling on the plantar surface

of the calcaneus. In Achilles insertional tendinitis, the tenderness occurs in the site where the tendon is near its insertion on the calcaneus. Retroachilleal bursitis and retro-calcaneal bursitis can be painful. The subtalar joint is too deep to enable accurate palpation, and effusion is rarely observed during inspection. The midtarsal, intertarsal and tarsometatarsal joints can be palpated. Tenderness of the metatarsophalangeal joints can be evaluated by gently compressing the metatarsal heads (metatarsal compression test). Chronic synovitis of the metatarsophalangeal joints often causes toe deformities, loss of the normal plantar fat pad under the metatarsal heads, formation of callus, enlargement of the forefoot (metatarsal) due to the weakening of the transverse metatarsal ligament. The interphalangeal joints of the toes are also palpated for tenderness, synovial thickening and effusion (5).

Routine foot radiography includes standing anteroposterior, standing lateral and oblique radiographic views. External oblique radiography is used to view the accessory navicular and peri-navicular joint. In the ankle, standing anteroposterior and lateral mortise radiographies are used. The increased medial clear space and tibiofibular clear space in the mortise radiography suggests us a syndesmosis injury. Detection of displacement more than 10 mm in the stress radiographs is a valuable finding in terms of instabilities. Taking account of sesamoid bone pathology, sesamoidgraphy may be requested (6,7). MRI is used to evaluate the soft tissues, to examine the cartilage, and to evaluate the bone edema and bone structures (7,8). CT is used to evaluate fracture, and to detect the conditions such as infection, osteochondral lesion, arthritis, osteonecrosis, and stress fracture non-union (7,9,10).

3.2 Muscle and tendon injuries

Gastrocnemius-soleus strain

The calf muscle on the posterior aspect of the lower leg comprises of three muscles: gastrocnemius, soleus and plantaris. Together they constitute the triceps surae. These muscles unite into the achilles tendon, and then insert into the calcaneus. It manifests as pain with activity in the calf area and USG is the gold standard in its diagnosis. This condition, colloquially named as calf strain, is addressed in 3 grades.

- **Grade 1 strain:** It is a first-degree or mild injury. A sharp pain is felt at the time of injury and the pain worsens with the continuation of the activity. There is little loss of strength with a muscle fiber disruption of less than 10%. Returning to sport would be expected within 1 to 3 weeks.
- **Grade II strain:** There is a loss of strength and decreased range-of-motion of the joint. Marked pain, swelling and often bruising are observed. Muscle fiber damage occurs in the range of 10-50%. Returning to sport would be expected within 3 to 6 weeks.
- **Grade III strain:** It is a third-degree and most severe injury resulting in a complete rupture of the muscle fibers, usually concomitant with a hematoma. Pain, swelling, tenderness, and bruising may appear within a few hours after the injury. Recovery of rupture after Grade 3 calf strain depends completely on the individual and treatment with an expectation of returning to sport within 2-3 months.

Conservative treatment is helpful in Grade 1 and 2, but surgical treatment may be required for the contractures in Grade 3 (11).

Achilles tendinopathies

The achilles tendon is the strongest and thickest tendon in the body (12). Achilles tendon disorders are evaluated as tendinopathy and rupture (Figure 2). Achilles tendinitis occurs as a result of achilles tendon degeneration. In physical examination, it appears as local tenderness and limited plantar flexion. Positive outcomes are obtained in treatment involving cold applications, anti-inflammatory medication, and rest (13). Degeneration developed as a result of chronic tendinitis or tendinosis prepares the ground for achilles tendon rupture when overstain is encountered. It manifests as local severe pain after acute injury. In the examination, the finding of a gap in the achilles tendon trace through palpation, and a positive Thomson test result are diagnostic criteria (13). MRI provides valuable information in diagnosis and treatment planning. The treatment can involve immobilization in plaster or surgery depending on the degree of injury. However, surgical treatment is prominent for athletes due to the advantages of low re-rupture risk and early returning to sport (14).

Peroneal tendon pathologies

It appears after ankle sprain. Peroneal tendinitis, peroneal dislocation, and rupture are the pathologies encountered. Peroneal tendinitis appears as a result of overuse, and edema and local tenderness are detected in the posterior lateral malleolus. Treatment involving limitation of activity and anti-inflammatory medication is recommended. In peroneal tendon tears, surgical debridement and primary repair can be performed. Peroneal tendon dislocation is the subluxation of the peroneal tendon from the fibular groove, tearing the retinaculum upon the contraction of the peroneal tendon during the eversion and dorsiflexion of the ankle. An avulsion fracture distal to the fibula can be detected in

radiography. Early detected dislocation can be treated by immobilization in plaster. Primary repair of the retinaculum is recommended in high level athletes (15,16).

Posterior tibial tendon dysfunction

Severe posterior tibial tendon insufficiency prevents high-performance sports. It is addressed in 3 stages.

- **Stage 1:** It manifests as increased calf pain after exercise. It is detected in the planus position of the foot before the heel reaches the valgus. There is no loss of strength in the tendon (17). Administration of local anesthesia inside the tendon sheath is effective for the suspected cases. USG and MRI are helpful radiological methods. A treatment involving cryotherapy and NSAIDs (nonsteroidal anti-inflammatory drugs) in the early period, and surgery in cases who are not responsive to 3-month treatment is recommended.
- **Stage 2:** The heel is in valgus and the medial arch is completely collapsed. It is surgically treated since conservative treatment is unsuccessful. It is unlikely that the athletes at this stage to resume their professional sports carrier (18).
- **Stage 3:** Acute rupture of the tibialis posterior tendon is considered at this stage. It is surgically treated (18).

3.3. Neurovascular entrapment syndromes

In athletes, entrapment syndromes may develop as a result of the pressure exerted on the surrounding neural structures due to various reasons.

Saphenous and sural nerve entrapment

It is very uncommon. It is typically associated with the scar tissue developed after surgical procedures. Conservative treatment may be successful. However, embedded nerve ending with the neurolysis or resection of neuroma is indicated in persistent cases (17).

Peroneal nerve entrapment

It is typically encountered after inversion ankle sprain, or with facial defects. Clinically, it manifests as pain and tingling over the dorsum of the foot. The symptoms exacerbate with plantar flexion and inversion. Tinel's sign (diffuse paresthesia in the foot with prolonged pressure on the nerve) can be observed. Conservative treatment should be planned in the early period. NSAIDs, injections and physical therapy can be used. In cases where conservative treatment is not helpful, the nerve may need to be released through fasciotomy (19).

Tibial nerve entrapment

Tibial nerve compression is also referred as tarsal tunnel syndrome. Tenosynovitis, synovial or ganglion cysts, lipomas, nerve sheath tumors, fractures, and accessory muscles may be the cause of tarsal tunnel syndrome, typically manifests with complaints of burning on the plantar and medial surfaces of the foot. Tinel's sign may be present during physical examination. EMG can be used for diagnosis. If no mass-related compression, typically conservative treatment involving: NSAIDs and tricyclic antidepressants may be helpful. When conservative treatment is not helpful in cases associated with mass, surgery is recommended following MRI to identify the formation and type of the mass (19).

Medial plantar nerve entrapment

Medial plantar nerve entrapment, which takes the sensation from the plantar and medial aspects of the foot, typically appears as a result of the pressure exerted by orthopedic devices. It is most commonly encountered at the junction of the flexor digitorum longus and the flexor hallucis longus tendons. This condition, which is also known as Jogger's foot, benefits from conservative treatment substantially (19).

Interdigital nerve entrapment

Interdigital neuritis is also named as “Morton's neuroma”. It is the compressive neuropathy of the interdigital nerve which is typically seen between the 3rd and 4th metatarsals. For this condition, whose pathophysiology has not been understood yet, microtrauma is the most highlighted theory. It is presented with pain, burning and numbness on the plantar surface of the foot. The symptoms exacerbate with high-heels and narrow shoes. During palpation, diffuse tenderness is present between the metatarsals. Clinical findings as well as contrast-enhanced MRI of the foot are often needed for diagnosis. Conservative treatment should be planned first. Shoe modification is one of the most crucial treatment parameters. Metatarsal pads and corticosteroid injections can be used. Neuroma excision can be applied in cases who are not responsive to conservative treatment (7,8,19).

3.4. Chronic exercise related compartment syndrome

It is more common in cyclists and runners. It is a condition with increased pain at the time of activity, limiting the performance substantially. In severe cases, paresthesia can also be observed upon the compression of the peroneal nerve. Its difference from the stress fracture is the rapid relief of pain and swelling with rest. In the diagnosis, compartment pressures should be measured before, during, and after

exercise. Pressures above 20 mm Hg 5 minutes after exercise, above 15 mm Hg during rest, and 30 mm Hg above the pre-exercise pressure 1 minute after the exercise can be helpful establishing the final diagnosis. Fasciotomy can be indicated in resistant cases who are not responsive to conservative treatment and activity modification (19).

3.5. Cartilage and bone-related pathologies

Chondral lesions

Ankle chondral lesions are most common in the talus. Although trauma is the most common cause, endocrine pathologies, delayed ossification, avascular necrosis and chronic microtraumas are accused in the etiology. Its clinical representation is typically deep pain after putting weight. Radiography is the first choice for diagnosis; however, CT or MRI may be needed in the evaluation of osteochondral lesions. MRI is especially notable in the diagnosis of non-displaced lesions and isolated chondral injuries. Conservative follow-up can be implemented in the early stages of talus osteochondral lesions but surgical treatment is recommended for severe cases. The available surgical treatment methods include primary detection of the lesion, arthroscopic debridement, and bone marrow stimulation (drilling and microfracture), mosaicplasty, autologous chondrocyte implantation, allograft, surface replacement arthroplasty. Arthroscopic debridement and microfracture stand outs as a minimally invasive technique where primary lesions are treated very successfully as well as long-term satisfactory results are obtained (Figure 3).

Ankle impingement syndromes

Ankle impingement syndrome most commonly appears in the anterolateral region in athletes (20). It typically manifests as chronic anterolateral ankle pain developed after ankle sprain. Insufficient healing,

inflammation and scar tissue formation developed after sprain leads to synovitis presentation. Osteophytes that may cause osseous impingement can be seen in radiography. MRI is the diagnostic tool for soft tissue related impingements (19). Conservative treatment involving activity modification and nonsteroidal anti-inflammatory drugs is planned as initial treatment. Arthroscopic debridement of osteophyte, or excision of hypertrophic soft tissue is recommended in cases who are not responsive to the treatment (20,21).

Stress fractures

Stress fractures occur when the micro-fractures formed as a result of repetitive loads to the bone exceed a certain threshold, giving radiological findings. It is more common in sports requiring jumping (20). It is most commonly encountered in the 2nd metatarsal bone, and commonly encountered in the 5th metatarsal bone, navicular bone and calcaneus. The stress fracture in the 2nd metatarsal bone is named as March fracture. The first complaint in application is long-standing foot pain that worsens with activity. Radiography is often sufficient for diagnosis. Further examination by MRI can be implemented for suspected cases. The treatment involves limitation of activity for about 6-8 weeks (22). It is more common in ballet dancers than other athletes. 5th metatarsal stress fracture is more common in overweight athletes and conservative treatment is less likely to be successful in this group; osteosynthesis screw treatment is recommended for the cases with refractory pain. Radiography is not sufficient for the stress fractures of the navicular bone. Further MRI and CT scan is necessary, and the treatment involves immobilization in plaster for 6 weeks, and osteosynthesis screw for refractory cases (23).

References

1. Elliot S. Mendelson, MD ve C. Max Hoshino, MD thomas G. Harris. Characterizing the Anatomy of Uninjured Ankle Syndesmosis. February 2014, Orthopedics, s. e157-e160.

2. Miller M. Core knowledge in orthopaedics. Philadelphia : Elsevier, 2006.

3. Hsu J, et al. AAOS atlas of orthoses and assistive devices. Philadelphia : Elsevier, 2008.

4. Adams J, et al. Emergency medicine. Philadelphia : Elsevier, 2006.

5. Dyck P, Thomas PK. Peripheral neuropathy. Volume 4. Philadelphia : Elsevier, 2006.

6. Zoga AC, Schweitzer ME. Imaging sports injuries of the foot and ankle. Magn Reson Imaging Clin N Am. 2003 May;11(2):295-310.

7. Schweitzer ME, Haims AH, Morrison WB. MR imaging of ankle marrow. Foot Ankle Clin. 2000 Mar;5(1):63-82.

8. Kömür B, Güler O, Mutlu S, Yılmaz B, Yücel B, Duymuş TM. Concomitantly intra-articular fracture of proximal condylar second and third proximal phalanges: A rare case report. International Journal of Surgery Case Reports. 2016;24:94-96.

9.Yılmaz B, Acar B, Kömür BH, Egerci OF, Köse Ö. Coronal plane talar body fracture associated with subtalar and talonavicular dislocations: A casereport. The Foot and Ankle Online Journal. 2016;9(4):3 Doi: 10.3827/faoj.2016.0904.0003.

10. Kömür BH, Yılmaz B, Katı YA, Turan A, Kılıçaslan OF, Köse Ö . Fracture of the entire posterior process of the talus: A case report and

review of the literature. International Journal of Orthopaedics Sciences. 2017;3(1):640-644.

11. Bryan Dixon J. Gastrocnemius vs. soleus strain: how to differentiate and deal with calf muscle injuries. Curr Rev Musculoskelet Med. 2009 Jun;2(2):74-7.

12. Garrick JG, Requa RK. The epidemiology of foot and ankle injuries in sports. Clin Sports Med. 1988 Jan;7(1):29-36.

13. Dick R, Sauers EL, Agel J, Keuter G, Marshall SW, McCarty K, et al. Descriptive epidemiology of collegiate men's baseball injuries: National Collegiate Athletic Association Injury Surveillance System, 1988-1989 through 2003-2004. J Athl Train. 2007 Apr-Jun;42(2):183-93.

14. Dick R, Lincoln AE, Agel J, Carter EA, Marshall SW, Hinton RY. Descriptive epidemiology of collegiate women's lacrosse injuries: National Collegiate Athletic Association Injury Surveillance System, 1988-1989 through 2003-2004. J Athl Train. 2007 Apr-Jun;42(2):262-9.

15. Swenson DM, Yard EE, Fields SK, Comstock RD. Patterns of recurrent injuries among US high school athletes, 2005-2008. Am J Sports Med. 2009 Aug;37(8):1586-93.

16. Boytim MJ, Fischer DA, Neumann L. Syndesmotic ankle sprains. Am J Sports Med. 1991 May-Jun;19(3):294-8.

17. Trevino S, Gould N, Korson R. Surgical treatment of stenosing tenosynovitis at the ankle. Foot Ankle. 1981 Jul;2(1):37-45.

18. Myerson MS. Adult acquired flatfoot deformity: treatment of dysfunction of the posterior tibial tendon. Instr Course Lect. 1997;46:393-405.

19. Mark D. Miller, Stephen R. Thompson. Miller Review of Orthopaedics 7th.: Elsevier . 978-0-323-35517-9.

20. Walls RJ, Ross KA, Fraser EJ, Hodgkins CW, Smyth NA, Egan CJ, et al. Football injuries of the ankle: A review of injury mechanisms, diagnosis and management. World J Orthop. 2016 Jan 18;7(1):8-19.

21. Walls RJ, Ross KA, Fraser EJ, Hodgkins CW, Smyth NA, Egan CJ, et al. Football injuries of the ankle: A review of injury mechanisms, diagnosis and management. World J Orthop. 2016 Jan 18;7(1):8-19.

22. Iwamoto J, Takeda T. Stress fractures in athletes: review of 196 cases. J Orthop Sci. 2003;8(3):273-8.

23. Assesment of the foot and ankle in elite athletes. Schon, LC. 2,: Sports Med Arthrosc, 2009, Cilt 17. pp:82-86.

Figure 1. Ecchymosis in the lateral part of the foot and ankle due to Anterior talofibular ligament rupture

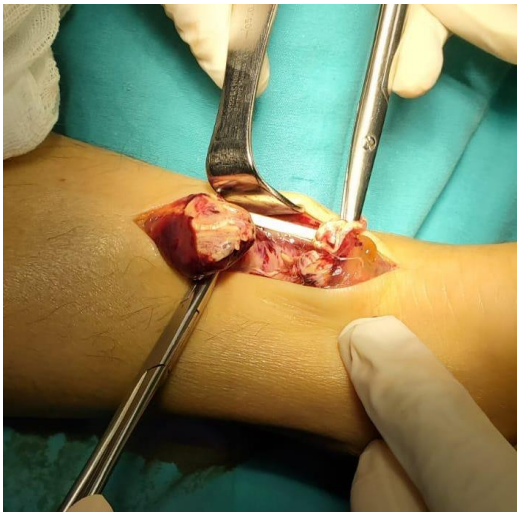

Figure 2. Achilles tendon rupture

Figure 3. Osteochondral lesion at talar dome (red arrow)

III. SPINE PROBLEMS IN ATHLETES

1.CERVICAL

Orhun Çelik, MD

University of Health Sciences, Fatih Sultan Mehmet Training and Research Hospital, Department of Orthopaedic Surgery and Traumatology, Istanbul-Turkey

Murat Kaya, MD

Marmara University Hospital, Department of Orthopaedic Surgery and Traumatology, Istanbul-Turkey

Mehmet Bülent Balioğlu, MD, Assoc.Prof.

University of Health Sciences, Fatih Sultan Mehmet Training and Research Hospital, Department of Orthopaedic Surgery and Traumatology, Istanbul-Turkey

1.1. Introduction

In this section, problems according to cervical part of spine will be discussed. Traumatic cervical spinal injuries are common in athletes that compete in contact sports such as football, wrestling, ice hokey or sports that demand excessive physical activity such as triathlon. These athletes face injuries varying from minor sprains and strains to serious neurologic consequences. During the last three decades, the incidence of cervical spinal injureshave significantly decreased. However, precautions still must be taken to avoid serious injuries. 85% of cervical spinal injuries occur due to axial loading by compressive forces applied on the head. Cervical neck loses lordosis by cervical flexion. Cervical spine becomes so flat that neck muscles can't absorb axial loading forces. As a result, the cervical spine becomes more vulnerable to injury. This alignment disrupts appropriate force distribution to thorax. The explained mechanism is the primary reason for these injuries to cause cervical fracture, dislocation and quadriplegia. Injuries may involve the structural components of the

vertebra (bones, discs, ligaments) and/or neural components (brachial plexus, nerve roots, spine). These injuries are generally minor so the patients fully recover. However, athletes with prior cervical injuries are more vulnerable to injuries causing compression fractures, neural arc fractures and radiographic findings of instability. Furthermore, serious clinical syndromes such as complete spinal cord injury and transverse myelopathy may occur resulting with neurological damage (1,2).

In the next section, problems according to the cervical region of the spine will be summarized in a more detailed manner.

1.2. Cervical Pain, Sprain and Strain

Sprain, often seen in athletes, is generally caused by minor injuries. Sprains of ligaments and muscles result with soft tissue contusion. Direction and type of injury determines severity of the injury. A collision during the sportive activity may cause a ligamentous injury resulting in instability. The patient may complain of localized pain spreading down the arms and a feeling of jammed neck. Typically, cervical range of motion is limited. Local pain may indicate soft tissue injury. Neurologic deficit may not be seen controversially. Such patients can be treated with cervical immobilization (1).

Anteroposterior, lateral and odontoid views of the cervical vertebra are useful when radiographic examination is needed. Lateral flexion-extension views can be applied and examined in a more detailed way,if the athlete is less symptomatic. Magnetic resonance imaging (MRI) or bone scintigraphy can be useful ifpain occurs by movement and joint decreased range of motion or radicular symptoms are detected. Basically, the treatment is determined according to severity of the injury. Cervical collar for immobilization and analgesic agents can be used until painless full range of motion is obtained (1).

An athlete involved in a collision injury must be taken out of the sportive activity and should be examined by a healthcare professional for any head or neck injury. Basic emergency management principals must be followed (airway, breathing, circulation). Cervical neck injury must be ruled out (3). The injuried athlete must be examined according to Glasgow Coma Scale (<15) and athlete's consciousness should be considered. Progressive worsening situation with vomiting, numbness of the limbs, seizure, neurologic symptoms and potential spinal injuries are decisivefor the patientto be transferred to a hospital (4).

No significant relation is reported between cervical pain and parameters such as; age, athletic condition, body mass index, years in sports and number of competitions an athlete has been involved in. However, according to some studies, older age is reported as a risk factor for sportive injuries. In addition to this, years in sports have been reported to be in significant relation with cervical pain. There comes out a hypothesis that cervical-spinal pain is in close association with overuse injuries. ~~Plus~~Moreover, a significant relation is identified between cervical pain and previous history of sportive injuries. It should be considered that such traumatic injuries may occur at any age.

Cervical-spinal pain can be broken down to three subgroups. Acute pain is defined as a period of time shorter than seven days. It is more related to tendon, ligaments and fascia. Subacute pain is defined as a period of time longerthan seven days but shorter than three months. In this group, facet joints may be involved too. Chronic pain is defined as a period of time longer than three months and such pain is closely related to disc pathologies. Subacute and chronic pain is significantly related to important morphological and structural changes in contrast with acute painwhich can recover in a short amount of time.

Conservative treatment is often indicated and enough for cervical-spinal pain. Medical treatment (anti-inflammatory agents, muscle relaxants etc.), physical therapy and injections are various methods for conservative treatment. However, surgical intervention may be needed for particular athletes.

Triathlon is a sport, which includes parts of swimming, cycling and running in various distances. In a study, cervical pain was identified to be 47.6% in triathletes. Depending on the duration of symptoms, 15.4% was found to be disc related and 64% was found to be sports related. Such cervical spinal problems lead to chronic cervical diseases and they have negative effects on training and athletic performance. Cervical pain and overuse injuries are pretty common among cyclists too. The two main risk factors for chronic cervical-spinal diseases are; sportive injuries and overuse injuries. Among recreationalcyclists, cervical pain incidence due to overuse injuries was identified as 50%.

Spinal problems related to sports activities can be treated nonoperatively. Massage, chiropractic medicine, physiotherapy and medical intervention methods are found to be useful among triathletes. Athletes with chronic pain should have a decrease in weekly training time and number of competitions participated. Lack of participation and training may significantly affect athlete's quality of life (5).

1.3. Cervical Disc Diseases

Acute traumatic disc herniations may result in cervical cord compression and lead to temporary or permanent quadriparesis/quadriplegia. Consequently, the athlete suffers acute paralysis of four extremities, lack of pain and temperature sensation. Radiologic modalitiessuch as MRI or CT and myelography combination

may confirm diagnosis. Permanent radicular pain or myelopathy should be treated operatively (1).

In athletes involved in certain sports (e.g. football), cervical spondilolythic changes without herniation or neurological findings are very common. Abnormal narrow disc space and early degenerative changes without any clinical findings have been identified among these group (7%). This is thought to be a result of repeated excessive loadings to the cervical spine. In MRI sections, diffuse disc bulging may be detected without focal disc herniation. Treatment is often modification of daily activities and nonoperative intervention.

Pathologies such as; congenital spinal stenosis, posterior ligamentous defects or herniated nucleus pulposus may be identified among athletes. These pathologies are generally asymptomatic in normal population. However among athletes involved in contact sports there is an increased risk of injury. All contact sports should be avoided for thosehaving prior cervical spinal operation due to disc herniation. They may be able to return to sports after postoperative bony fusion is identified (2).

1.4. Cervical Spinal Stenosis

In athletes, disc problems in the cervical region may represent itself with severe spondylothic changes. These changes may cause uncovertebral joint hypertrophy. This leads to narrowing of neural foramens encircling nerve roots. Furthermore, whole spinal canal may be filled with disc-osteophytes, which leads to the acquired stenosis of the spinal canal.

Transient Spinal Cord Injury (TSCI); is one of the most complex situations an athlete may suffer. Weakness, quadriplegia and combined sensory deficits occur on all four limbs. Symptoms may fade away in 15-30 minutes but also last as long as 24-48 hours. Usually, patients fully recover from TSCI without residual pain or limitation of movement at the

cervical region. After recovery, neurological examination is normal. The pathological mechanism is compression of the spinal cord between the posterior-inferior cervical vertebra and the lamina of the neighboring vertebra. Threshold, which the spinal cord can tolerate, is crossed without disrupting spinal structural integrity. Spinal stenosis is the most common underlying pathology in patients suffering TSCI (2).

1.5. Congenital Anomalies

Generally cervical congenital anomalies may change the mechanic stability of cervical spine. Especially in athletes, minor traumatic events may have an increased potential for cervical spinal injury if there is an underlying congenital spinal anomaly. Congenital anomalies of cervical spinal are basically a result of segmentation and formation anomalies.

Klippel-Feil syndrome is a cervical segmentation deficiency. It is a wide spectrum disease involving lack of mobile segments of the vertebra. The syndrome is classified as Type I and Type II especially to identify the risks for football players. Type I has a long fusion mass inside it and Type II has just one or two fused segment. Loss of mobility increases with more segments involved. As a result, stress on the adjacent normal segments increases. This significantly disrupts the ability of cervical vertebra to absorb and distribute loading forces properly. Some athletes may have atlanto-occipital congenital segmentation deficiency. In this case, insidious compression may occur at the posterior edge of the foramen magnum of spinal cord's posterior colon.

Formation deficiency, leading to pathologies such as odontoid agenesis or hypoplasia and developmental osodontoideum, may cause serious atlantoaxial instability. Spina bifida occulta is defined as formation deficiency of the posterior arc. This situation is usually asymptomatic and incidentally diagnosed during radiographic examination (1).

1.6. Fractures-Dislocations Due to Cervical Spinal Trauma

Sports related injuries of cervical region could be listed in order according to increasing intensity, as follows: disruption of connective tissue, bone tissue and neural structures. Especially unstable fractures and dislocations may lead to spinal cord injuries. Axial loading is the primary traumatic mechanism in sports related cervical spinal injuries. Cervical vertebrae, paravertebral muscles, intervertebral disks and the normal lordosis of the cervical spine mostly absorb the energy caused by the collision. However, when neck is in 30 degrees of flexion, normal lordotic curvature becomes flat. Due to this change, axial loading forces on the head in certain sports are directed to a straight column. In this case, cervical spine cannot distribute the loaded forces and axial loading causes compressive deformation of the intervertebral discs. This leads to angular deformity and folding of the spine and it may result in fracture, subluxation or luxation. Cervical spinal injury and other mechanisms leading to fractures can occur with a combined force of rotation and compression. (Figure 1). Structures adjacent to cervical spine may be disrupted as a result of flexion, extension, rotation and shearing forces during the collisional trauma.

2.1. Cervical Neurologic Pathologies

During a spinal vertebral fracture, fragments of bone or herniated disc materials may harm spinal cord and cause neurologic injury. This may lead to several clinical syndromes according to the type and severity of cervical spinal trauma. Displacement of bone and secondary pathologies like hemorrhage, ischemia and edema creates the clinical findings.

Complete spinal cord injury is a transverse myelopathy. All spinal functions are lost below the level of lesion. However, incomplete spinal cord injuries are generally vascular origin and represents itself with certain

patterns such as; central cord syndrome, anterior spinal cord syndrome, Brown-Sequard syndrome, posterior column syndrome and burning hands syndrome (2).

Central cord syndrome causes incomplete motor function loss and leads to different degrees of upper and lower extremity weakness. Usually, it is caused by hyperextension type injuries. Weakness of the upper extremities is more significant compared to lower extremities. This is caused by hemorrhagic and ischemic injury to corticospinal tracts and the unique somatotopic localization of these tracts.

Anterior spinal cord syndrome is caused by injuries to the anterior spinal artery, which provides the blood supply of 2/3 anterior part of the spinal cord. This leads to ischemia of the anterior region and equal motor deficit of the upper and lower extremities.

Brown-Sequard syndrome is a cervical cord pathology that occurs at one half of the spinal cord. It leads to loss of ipsilateral motor function and contralateral spinotalamic function. This syndrome usually occurs with other incomplete injuries rather than in an isolated form. Often a combination of Brown-Sequard and central cord syndrome is seen. Presentation of this pathology is usually; unilateral motor loss, contralateral sensory deficit and weakness of extremities with a greater degree in the upper extremities.

Posterior cord syndrome is a seldom seen clinical entity. It causes dorsal column function loss. However, corticospinal and spinothalamic tract functions remain intact. This syndrome is related to isolated ischemia of the posterior spinal artery.

Burning hands syndrome is characterized by burning dysesthesias and paresthesias in both hands. It is often seen in athletes, which participate in

contact sports like wrestling and football. Repetitive cervical trauma is thought to be the cause.

Transportation of the athlete should be done carefully when the athlete is unconscious. Cervical spine should be immobilized on a rigid spinal board. The patient's airway access should be secured. During these situations, athlete should be evaluated for head injury. The case must be evaluated as a cervical vertebral fracture if the athlete is unconscious or having symptoms like paralysis, neck pain, motor or sensory deficit (2).

Sometimes a combination of symptoms indicating central nervous system and peripheral nervous system injury is seen. This special type of injury is called 'burners' or 'stingers' and it is seen usually in football players and wrestlers. The pathologic mechanism of this injury is basically head to should contact causing lateral flexion of the head and straight traction force to the ipsilateral shoulder in inferior direction. This trauma mechanism causes the brachial plexus to stretch and get injured (Figure 2).

2.2. Brachial Plexus and Root Injury

Neuropraxia of nerve roots or brachial plexus is one of the most common cervical spinal injury among athletes in sports, which put the athlete in high risk for head and neck injury (e.g. football). After such injuries, burning or stinging feeling in a patient may suggest a serious problem and it must be carefully examined. If the symptoms occur in both upper extremities, spinal cord is thought to be affected rather than nerve root or plexus. Neuropraxia is caused by compression or traction injury of multiple nerve roots or the brachial plexus. Symptoms are temporary stinging or burning feeling. Traumatic injuries that cause neuropraxia, can affect the brachial plexus directly or indirectly. Indirect trauma mechanism starts with sudden shoulder depression and lateral flexion of the head to the unaffected side. This causes the brachial plexus to stretch. In addition

to this, simultaneous head rotation to the side of the affected arm causes the neural foramens to narrow down and nerve roots get stuck (Figure 2). Direct jamming of the brachial plexus may also cause neuropraxia. An inappropriate mobile shoulder-pad may cause compression on the Erb point (in front of the neck, trunk of the brachial plexus 2-3 cm above clavicle). This causes brachial plexus to get jammed between the shoulder-pad and upper medial scapula (1).

Athletes may complain of unilateral muscle paresis and a type of shoulder or/and arm pain referred as 'dead-arm'. Symptoms are not progressive and regress in a short amount of time. Burning pain fades out in seconds to minutes. Weakness symptoms usually recover in 24 hours. Varying degrees of weakness of muscles innervated by the superior trunk of the brachial plexus may last up to 6 weeks. A cervical spinal examination should be made. Usually a painless full range of motion without neck pain or palpable deformity is observed. Symptoms improve rapidly. The athlete can return to sportive activities if muscle power is full and normal. If symptoms continue and painless range of motion cannot be obtained, cervical spinal radiography and further evaluation of the patient should be made. Until recovery of full muscle power, sportive activities should be restricted for the athlete. Protective orthosis and equipment to help limit neck extension and lateral head flexion (neck-shoulder-chest thermoplastic full contact orthosis under shoulder-pads e.g. in football players) can be useful for reducing risk and severity of compressive brachial plexus injuries (1).

2.3. Spinal Cord Neuropraxia

Cervical cord neuropraxis is defined as a unique entity. It is the temporary quadriplegia occurring after hyperflexion and hyperextension of the cervical region after axial loading. It is a temporary situation and

usually symptoms relieve in 10 to 15 minutes. Rarely, symptoms may last up to 48 hours. Radiographic examination is clean for fracture or a luxation. However; indications for congenital stenosis, Klippel-Feil syndrome, intervertebral disc disease or acquired stenosis are present.

'Burning hands' syndrome is defined as a variant of central cord syndrome caused by edema and vascular insufficiency. Strength, reflexes and sensation are maintained. However, burning dysesthesias and paresthesias occur in a 'glove-like' fashion. While radiologic findings may be present or not, this clinic representation can be related to a fracture or a luxation. In addition to roentgenography, MRI or postmyelography CT (for patients who are not suitable for MRI) can be useful to evaluate neural structures of athletes with cord injury symptoms. Cord compression can be caused by a clamp-like mechanism, which was described by Penning for the first time (Figure 3)(1).

Spinal cord gets jammed between posteroinferior edge of the upper vertebra and the anterosuperior lamina of the neighboring vertebra, when cervical neck is in hyperextension position. In addition, folding of posterior longitudinal ligament and ligamentum flavum causes further narrowing of the spinal canal. However in hyperflexion position, a jamming occurs between the lamina of the superior vertebra and the posterosuperior edge of the neighboring vertebral body. As a result, athletes with congenital or acquired cervical stenosis are more prone to spinal cord neuropraxia after injuries by axial loading forces to neck in hyperextension or hyperflexion positions.

Canal diameter is calculated in order to evaluate congenital stenosis (The distance from center of posterior side of vertebral body to the closest point along the spinolaminar line, on lateral view) (Figure 4). Normally, middle sagittal diameter is between 14 and 23 millimeters (mean value is

17mm). Diameter below 13 millimeters is defined as stenosis. <13 mm is relative, <10 is definite stenosis. Pavlov for the first time suggested using the ratio of segmental sagittal diameter to the width of vertebral body. This ratio should be below 0.8 to define it as a congenital stenosis.

For stenosis, Torg-Pavlov ratio (canal / vertebral body width) is accepted below 0.8 (normal value is 1.0). However, Torg-Pavlov ratio highly depends on the technique. It is not predictive and it may not give correct results for large athletes. Independently from the ratio, stenosis and jamming may occur in the canal due to soft tissue elements (disc, ligamentum flavum etc.). Thus, stenosis cannot be properly diagnosed just by evaluating the bony structure. In athletes involved in sports like football, the risk of quadriplegia can be predicted radiographically for a particular subgroup of such players. Abnormal conditions like congenital stenosis, loss of cervical lordosis and post-traumatic pathologies were identified among radiographic analysis of these players. The identified pathologic conditions were related to a tackling technique called 'spearing' (using the top of the helmet to tackle the opponent). This condition is defined as 'speartackler's spine' and it is an absolute contraindication for playing football (1).

3.1. Cervical Vascular Injuries in Athletes

Carotid and vertebral arteries are at risk of being damaged by traumatic cervical spinal fractures and luxations or direct compressive forces. Vertebral arteries may be injured with fractures or luxations at or above the level of C6. There are various pathological mechanisms for vascular injury: Direct compression by bony fragments, stretching of vertebral artery due to vertical movements or an expanding traumatic haematoma inside foramen transversarium. In addition to this, traumatic intimal ruptures inside blood vessels may create thrombotic materials. Temporary ischemic attacks may occur due to thrombotic embolism of anterior and middle

cerebral arteries. MR angiography, CT angiography and diffusion MRI are valuable diagnostic methods for ischemic cranial pathologies (2).

Vertebral artery dissection (VAD) is a rare but catastrophic vascular pathology seen in athletes involved in contact sports. There are multiple etiologies for VAD. Common cause is head or neck trauma. There is a wide spectrum of VAD etiology. Predisposing factors, genetic tendency, type of trauma and severity of the trauma are some parameters for VAD etiology. Many trauma mechanisms are described for VAD in athletes. Especially blunt trauma below the level of ear during martial arts competitions are identified to be causing VAD in athletes. Another traumatic mechanism is excessive movement of cervical region of spine. Direct blow to the head or neck can cause such excessive movements. Among particular athletes, risk-reducing strategies must be developed in order to minimize vascular trauma. Topics like; competition rules, personal protective equipment and athlete education must be handled by authorities in order to avoid devastating consequences of head and neck trauma (6,7).

4.1. Cervical Pathologies in Special Athletes

Patients with Down syndrome are in risk for atlantoaxial instability (AAI). Atlantoaxial instability or atlantoaxial subluxation is defined as increased movement of cervical vertebral joint articulation between the first (atlas) and the second (axis) vertebrae. According to studies, the incidence of AAI among Down syndrome population varies from 6.8% to 27%. Risks related to AAI are neurologic injuries resulting from excessive movement of cervical vertebrae. Although rarely, cervical vertebrae with increased mobility may compress spinal cord and damage it. Knowing the biological, psychological and social benefits of sportive activities for Down syndrome population, safe physical activity and training should be provided for this group of patients (8).

References:

1. Thomas BE, McCullen GM, Yuan HA. Cervical spine injuries in football players. J Am AcadOrthop Surg. 1999 Sep-Oct;7(5):338-47.

2. Bailes JE, Petschauer M, Guskiewicz KM, Marano G. Management of cervical spine injuries in athletes. J Athl Train. 2007 Jan-Mar;42(1):126-34.

3. Cahill PJ, Refakis C, Storey E, Warner WC. Concussion in Sports: What Do Orthopaedic Surgeons Need to Know. J Am AcadOrthop Surg.2016 Dec;24(12):e193-e201.

4. McCrory P, Meeuwisse WH, Aubry M, Cantu B, Dvorák J, Echemendia RJ, et al. Consensus statement on concussion in sport: the 4th International Conference on Concussion in Sport held in Zurich, November 2012. Br J Sports Med. 2013 Apr;47(5):250-8.

5. Villavicencio AT, Hernández TD, Burneikiene S, Thramann J. Neck pain in multisport athletes. J Neurosurg Spine.2007 Oct;7(4):408-13.

6. Torg JS, Glasgow SG. Criteria for return to contact activities following cervical spine injury. ClinJ SportMed. 1991;1:12-26.
7. Saw AE, McIntosh AS, Kountouris A. Vertebral artery dissection in sport: Expert opinion of mechanisms and risk-reduction strategies. J ClinNeurosci.2019 Oct;68:28-32.

8. Tomlinson C, Campbell A, Hurley A, Fenton E, Heron N. Sport Preparticipation Screening for Asymptomatic Atlantoaxial Instability in Patients WithDown Syndrome. Clin J Sport Med. 2018 Aug. Doi:10.1097/JSM.0000000000000642.

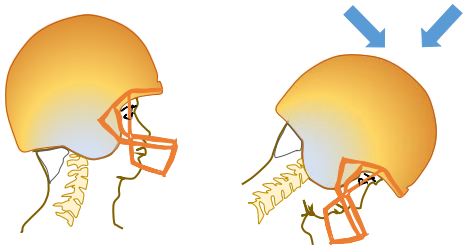

Figure 1. Mechanism of cervical spinal injury

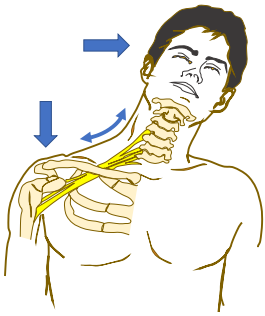

Figure 2. Mechanisms of indirect cervical trauma

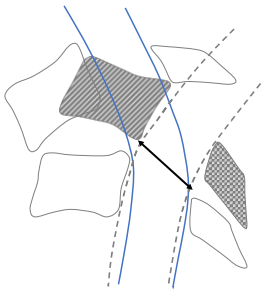

Figure 3. Cord compression can be caused by a clamp-like mechanism

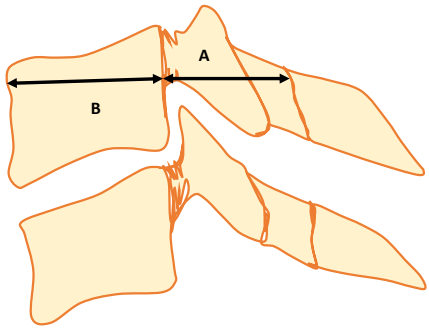

Figure 4. Calculation of spinal canal diameter on lateral view: The distance between the center point of posterior side of vertebral body and the closest point along spinolaminar line.

2. THORACAL-LUMBAR-SACRAL

Emre Bilgin, MD

University of Health Sciences, Fatih Sultan Mehmet Training and Research Hospital, Department of Orthopaedic Surgery and Traumatology, Istanbul-Turkey

Ahmet Kocabıyık, MD

University of Health Sciences, Fatih Sultan Mehmet Training and Research Hospital, Department of Orthopaedic Surgery and Traumatology, Istanbul-Turkey

Ahmet Onur Akpolat, MD

University of Health Sciences, Fatih Sultan Mehmet Training and Research Hospital, Department of Orthopaedic Surgery and Traumatology, Istanbul-Turkey

2.1.Introduction

Back pain is one of the most common symptoms among muscle and skeletal system disorders. Back pain among athletes is 1-30% (1,2). Biomechanic changes on lumbar region caused by excessive loading forces (acute macro trauma, repeated micro trauma and combinations of these) on spine make up the etiopathogenesis of back pain. Any anatomic structure that makes up the movement segment of spine can be a source of pain (3,4).

2.2.Lumbar Pain, Sprain and Strain:

This is the most common reason for athletes to be deprived of sportive activities. In adult athletes, the cause is usually mechanic factors (strain, muscle imbalance, biomechanical disruptions of lower extremity and decreased flexibility etc.). In adolescent athletes however, there are multiple causes of lumbar back pain such as; mechanic factors, growth

episodes, disproportional growth, lack of proper development of muscles and ligaments etc. (5-7).

Lumbar strain occurs due rupture of muscle fibers by eccentric loading or direct trauma. It may occur at different regions of a muscle-tendon unit. This is a reason for acute or chronic symptoms. Acute symptom is lumbar back pain occurring 24 to 48 hours after the trauma. However, patients define chronic pain as tiredness. Patients complain of pain after excessive exercise. These patients have a history of previous lumber pain attacks (8). Local sensitivity and pain is seen at lumbar region and paravertebral muscles. Range of motion is limited but neurologic examination is normal. In cause of a neurological finding, disc herniation must be ruled out. Pain of muscle spasm occurs at paravertebral muscles. However, pain of lumbar strain is located at the midline.

All patients must be examined by roentgenography because these athletes usually suffer repeated trauma. Magnetic resonance imaging (MRI) is necessary if neurologic symptoms exist. Increasing lumbar spinal flexibility is a way of avoiding lumbar strain. Body temperature increases by a warm-up of 30 minutes before physical activity. This increases blood circulation at extremities and enhances lumbar flexibility. In a patient experiencing lumbar pain, there is 3 times more risk of recurrence.

Nonoperative intervention is preferred initially. Non-steroid anti-inflammatory agents, short period of rest and physical therapy are some conservative methods to help relieve lumbar pain. Return to physical activity is recommended after; pain relief, restoration of flexibility and disappearance of spasm.

2.3.Lumbar Disc Pathologies

Vertebral disc is composed of gel-like nucleus pulposus covered by annulus fibrosus (9). Intervertebral disc is durable to compressive forces

by its elastic structure and high water content. On the other hand, annulus fibrosus is durable to rotational forces by its cross-linked structure. Disc pathologies are rare in young athletes (11%). It is more often seen in adult athletes (48%). In young patients, the intervertebral disc is more resistant than bone to biomechanic loading forces. This causes herniation if the disc in the endplate or the apophysis (9,10). In this manner, disc pathologies can be classified in two categories: Degenerative disc diseases and lumbar disc herniation.

Degenerative disc diseases: As a disc degenerates, it loses most of its water content. It becomes stiffer and its energy absorbing capacity decreases. In this case, repeated micro-trauma incidents cause athletes to suffer degenerative disc related problems. In addition to aging, excessive sportive activities also cause degenerative disc disease (11-13). There is a relation between sportive activity involvement and disc degeneration. Type of degeneration and its severity depends on type of sportive activity and amount of time spent doing it. Among weightlifters, severe disc degeneration is identified at upper vertebral levels. However among soccer players, less severe forms of degeneration usually occurs at L4-S1 interval (12,14). Relation between degenerative disc disease and lumbar pain is complex. This is because an athlete radiologically diagnosed with discopathy may be clinically asymptomatic. To conclude; lumbar pain, neurologic claudication and cauda equina in progressed cases may be seen due to degenerative disc diseases.

Roentgenography is valuable for diagnosis of bone and joint degeneration. Computerized tomography (CT) is useful for evaluation of the spinal canal, degenerative changes in facet joints. It is also an important method to view bony frame and neural foramens. MRI is a valuable diagnostic imaging method to scan soft tissue pathologies, radiculopathies, facet joints, sinovitis, foraminaland extraforaminal regions; signal changes

and loss of height can be identified in degenerative disc diseases. With electromyography, sensory and motor functions of nerves can be evaluated.

Usually, nonoperative treatment is preferred in athletes. It includes; rest, warm compression (or cold), non-steroid anti-inflammatory drugs, soft tissue mobilization and epidural injections. In addition to pain control, isometric exercises should be added to treatment. In these athletes, especially the back muscles must be strengthened. By the end of recovery period, specific sportive exercises (according to profession of the athlete) should be encouraged in athletes (13,15,16).

Lumbar disc herniation: This pathology is seen especially in athletes between ages of 20 to 35. Most common affected levels are L5-S1 and L4-L5. Combined effect of compression, anterior flexion and rotational forces cause disc herniation (14). This traumatic mechanism is seen often in sports like; soccer, wrestling, tennis, hockey, golf and gymnastics (12). Patients usually stand at a lumbar extension posture. Back pain occurs due to displacement of discs with anterior bending and backward movement. Increase in symptoms may be seen in situations like coughing or sneezing due to increase in intrathecal pressure. During physical examination dermatomes, muscle power and tendon reflexes must be evaluated. The straight leg raise test and Laseque test (which is a modification of the former) is useful to evaluate L4-L5-S1 nerve roots. Femoral stretch test is useful to evaluate L2 and L3 roots. Straight leg raise test is especially important to diagnose lumbar disc herniation. In some patients, cauda equina syndrome may be seen. This is an emergency situation representing itself with urinary and faecal incontinence.

Roentgenography is insufficient for diagnosis. CT is valuable for evaluating pathologies such as spinal canal diameter, osteophytic changes

of neural foramens and calcification of ligaments. Lumbar MRI is a valuable diagnostic method for lumbar disc herniation. It gives us detailed information about properties related to the disc herniation such as: Type and location of disc herniation, caudal/cranial migration of herniation, compression of nerve roots, neural foramens, facet joins and soft tissues like ligamentum flavum.In addition, MRI enables detailed evaluation of the spinal cord, cauda equina fibers and paravertebral muscles. Sensory and motor functions of the nerves may be evaluated with electromyography.

Non-operative intervention is sufficient for patients without neurological findings. This includes; pain control, activity modification and physical therapy. The only absolute indication for operative treatment is presence of cauda equina syndrome. Its clinical presentation is progressive neurologic deficit, perineal hypoesthesis and alsofaecal and urinary incontinence. All other pathologies are relative indications for operative treatment (17-19).

2.4.Spinal Trauma and Fractures

The most common area for spinal fractures is the thoracolumbar junction zone. Spinous and transverse process fractures can be seen due to direct trauma and torsional injury. Vertebral apophysial avulsion fracture can be seen in adolescents due to excessive contraction of extensor muscle groups. Especially in female athletes, pedicle and sacral stress fractures may occur due to repeated traumatic and overuse injuries (20,21). In adult athletes, axial loading and excessive flexion mechanisms may lead to vertebral compression fractures.

Pain usually begins instantly after exercise or trauma. Increase in pain while sitting or decrease while lying down, is an indication for fracture. Chronic lumbar pain resistant to conservative treatment indicates a pedicle

or sacral stress fracture. Increase in pain during extension points out a stress fracture of posterior elements. Pain with palpation is present at the area of vertebral fracture. On neurological examination, sensory and motor deficit may be present. Patrick's test is defined by increasing pain at the affected side of body while jumping on the ipsilateral leg. This test is found positive if there is a stress fracture present.

On roentgenography of compression fractures, loss of vertebral height and an increase in interspinous gap is present. Spinous process fractures can be identified on lateral view, whereas transverse process fractures can be identified on AP view. On CT, pedicle and sacral stress fractures can also be detected. Neural structures and posterior ligamentous tissues can be assessed with MRI. In some cases, bone mineral density testing is needed to identify osteoporosis.

Conservative treatment is initially preferred. Non-steroid anti-inflammatory drugs and vertebral brace usage is recommended. Osteoporosis, which is a risk factor, must be ruled out if a stress fracture is diagnosed. Relief from loading, pain control and treatment according to the pathology makes up the treatment. In case of instability or a kyphosis angle more than 20 degrees, operative treatment is indicated (21,22).

Full recovery and fusion may take up to two months. After clinical and radiologic recovery, physical therapy and functional restoration treatments begin. Full range of motion must be obtained before returning to sportive activities (23,24).

2.5.Spondylolysis / Spondylolisthesis

Spondylolysis is defined as anatomic defects occurring at pars interarticularis, which connects upper and lower facet joints of vertebrae. Spondylolisthesis is anterior displacement of the upper segment of spine on the lower segment. Wiltse and Jackson defined five types of

spondylolisthesis: Dysplastic, isthmic, degenerative, post-traumatic and pathologic (25,26). According to Meyerding classification, spondylolisthesis classification is made according to the degree of displacement: 0 degree meaning no displacement, degree I meaning 0-25%, degree II meaning 25-50%, degree III meaning 50-75% and degree IV meaning 75-100% displacement. If displacement is more than 100%, it is categorized as degree V (spondyloptosis) (27). This displacement is 90% at L5-S1 level and less commonly at L4-L5 level. This is because loading forces are most active at these levels while doing hyperextension movement. Among athletes, spondylolisthesis has a ratio of 8-15%. It is most commonly seen in athletes doing diving, dancing and wrestling (28).

In childhood and adolescence, developmental spondylolisthesis is the most common type. This type of spondylolisthesis covers dysplastic and isthmic types. It is seen in 40-50% percent of adolescent patients with lumbar back pain. There is a congenital anomaly of lumbosacral joints in developmental spondylosithesis disease. Pars interarticularis of L5 vertebra is intact but longer than normal. L5 vertebral body anteriorly and inferiorly displaces on sacrum. Thus, a pelvic retroversion occurs (29,30). Rotational loading forces cause spondylolysis in patients with dysplastic pars interarticularis. Thus, spondylolysis should be ruled out in young athletes with lumbar back pain especially the ones who are involved in equestrian sports (30).

In athletes, most common type is post-traumatic spondylolisthesis. It is the cause of 10% of all lumbar back pain. Listhesis is also seen in 50-80% of athletes with pars defect. Spondylolisthesis incidence increases especially in sports such as: Tennis, gymnastics, weightlifting, wrestling, rowing and dancing due to repeated hyperextension movement in these sports (27). It is usually asymptomatic. Tenderness at spinous process of L5 vertebra after a trauma may indicate an acute fracture of pars

interarticularis. Pain is a characteristic finding when lumbar spine is in hyperextension. Pain usuallyincreases with single-leg hyperextension test and more symptomatic at the affected side. Patients may complain from pain spreading from hip to posterior thigh while walking or standing. High degree cases may involve hamstring stiffness. Radicular pain is rarely seen. Phalen-Dickson sign is defined as presence of lumbar lordosis, posterior pelvic tilt, vertical sacrum and abdominal ridging while walking in squat position (with knee and hip flexion). In addition to this, lumbar step-off sign is made up of: Presence of an L shaped step-off at the patient's back with increasing lumbar lordosis, anterior displacement of upper spinous process compared to the lower, change of interspinous space with lumbar spinal flexion and extension while the patient is standing.

Roentgenography is the first step in diagnosis. It is typical to observe the ‘Scottish-dog sign’ on the oblique view (Figure 1). By scintigraphy, nonunion and low metabolic activity (cold in hot spot) at the defectivearea may be seen. CT is very useful to evaluate bony structure, whereas MRI is valuable to diagnose soft tissue and disc pathologies.

Objectives of treatment are; obtaining union, pain relief and enhance functional activity. Further follow-ups are suggested for asymptomatic patients. In symptomatic patients with unilateral pars defect, healing rate is 80% with a protective brace. However, this ratio is 5-8% in patients with bilateral pars defects. Union takes about 3 to 12 months with orthopedic brace and medical treatment modifications (29,31). Operative treatment is preferred for symptomatic or high degree spondylolisthesis cases. Pars repair or single level fusions are some of the operative treatment options (25).

2.6.Sacroiliac Pain

Sacroiliac joint (SIJ) pain originates from the joint itself or from the soft tissue around it. Its occurrence potential is higher in athletes involved in repeated or asymmetric loading (kicking, swinging, throwing and single leg stance). Most common sports for sacroiliac pain are; football, basketball, powerlifting, gymnastics, golf, cross skiing and rowing. Other risk factors include; systemic inflammatory diseases, pregnancy, difference in leg length, hypermobility, scoliosis, trauma, degenerative joint diseases and biomechanic anomalies (32-37).

The most common mechanism for acute SIJ pain is abrupt rotation and axial loading. However, most athletes experience progressive increase of symptoms after repeated microtauma. Actually, there is no diagnostic finding to demonstrate this pathology. Generally, patients complain of intense lumbar back pain and state that they cannot find a comfortable sitting position. Pain usually increases while running, going upstairs and while standing up (34,36,37). Pain is insidious in the beginning. However it increases at night and it may cause morning stiffness, which relieves with exercise. This may indicate rheumatologic etiology. Radicular symptoms are usually absent. Pain at lower back, posterolateral thigh, hips, inguinal area or abdomen may occur due to change in joint mobility or alignment as a result of abnormal stress loading. Tenderness may be present on SIJ and it can be provoked by certain tests (32,36,37).

Tenderness with sacral sulcus palpation is a significant but not a specific finding. Although there are certain tests that can be applied, diagnosis can be very challenging (32,34,36). Radiology rarely helps in diagnosis of SIJ dysfunction. However, radiological methods are recommended to rule out other pathologies with similar symptoms such as; infection, inflammatory arthropathy, fractures, anatomic anomalies or

neoplasms. In a study, existence of degenerative changes in asymptomatic adults was found to be 65%. Thus, radiological evaluation according to history and physical examination of a patient is very crucial (32). X-ray may not be sufficient for diagnosis. CTscan can be helpful to examine bone abnormalities, sacroiliac joint space and subchondral bone. MRI is preferred for the evaluation of inflammation, infection, stress fracture, structural lesions and anatomic variations. Bone scintigraphy may be used to evaluate SIJ pathologies but it is not a default method (34).

To conclude, physical examination and imaging methods are insufficient to differentiate SIJ pain and its symptoms from neighboring soft tissue pathologies. In this case, intra-articular injections are substantial with a diagnostic rate of 90%. The most certain diagnostic method is more than 75% symptomatic relief after injection (32). After such injection, an athlete must avoid sportive activities for 24 hours (34,37).

Managing the symptoms and fixing the underlying dysfunction are among the treatment objective. First line of conservative treatment is made up of; activity modification, topical and oral medication, cold compression, physical therapy and manual manipulation. Secondly in conservative treatment, bracing is suggested. Acupuncture, massage and yoga are some of the complementary medical treatments for SIJ pain. These methods are considered to be helpful but further studies are needed. Athletes are handled similar to general population. However, athletes require specific rehabilitation according to their sportive profession. Gradual return to sportive activity is necessary in athletes (32). After sufficient pain control, muscle imbalances must be managed. External hip rotators like the piriformis muscle are especially important because stiffness of these muscles is thought to be a reason for recurrence of symptoms. Agonist-antagonist relations of muscles must be taken into account. Among these athletes, tenseness is present usually at muscles such as; hip adductors,

piriformis, obturator internus, rectus femoris, tensor fascia lata, quadratus lumborum and latissimus dorsi. Generally, weakness is present at hamstrings, gluteus medius, gluteus maximus and lower abdominal muscles. Hamstring and gluteus maximus strength with proper flexibility is vital for an athlete. Athletes may return to specific sportive training only after regaining 75% their of original strength and flexibility. Particular attention should be paid at training and performance errors. These errors must be identified and fixed (34,37)

2.7. Sacral Stress Fractures

Sacral stress fractures are rare in athletes. They are caused by sportive activities like running or gymnastics, which involve repeated highly dynamic movements. Stress fractures are divided into two subgroups: insufficiency and fatigue fractures. Insufficiency fractures usually occur in elderly osteoporotic patients. Bone mineral density is very low in these patients and a normal stress force causes the fracture. Fatigue fractures however, occur in patients involved in intense athletic trainings where bone is under excessive stress. Etiologies and treatment strategies of these two types of stress fractures are different. Differentiating these two subgroups is important to determine appropriate medical management, rehabilitation and invasive strategies. Thus, optimal functional results can be achieved (38-40).

The main etiologic factor in both stress fractures is stress distribution from spine's vertical axis to sacrum and sacral ala. There are many other contributing factors: Leg length discrepancy, repetitive stress, progressive insufficiency of supportive muscles, changes in physical demands, environmental and genetic factors, training methods, shoe decision, training frequency/intensity/time, increase in sacral stress due to pelvic anteversion (41).

Sacral fatigue fractures occur when abnormal stress forces are loaded on a bone with normal quality. Typically, such type of fractures occurs in long distance runners and military personnel. It occurs due to repetitive physical activity, which puts excessive load on the sacrum. Sacral stress fracture incidence is less than 1% in general population but it can rise up to 20% in some studies. Gender is not as significant as for insufficiency fractures, which is more frequent in females. In addition to excessive mechanic loading, female athlete triad is an important etiologic component for sacral fatigue fractures in women. Triad contains amennorhea, poor nutrition and osteopenia. On the other hand, this triad's presence is not necessary for a fracture to occur in a woman. Repeated microtrauma starts bone remodelling. In addition to this, repeated cyclic stress causes increased osteoclastic activity connected to osteoblastic activity in the new bone tissue. Insufficient resting time for the new bone tissue to accumulate properly causes weakness and fracture consequently (42,43).

Sacral stress fractures present with severe; hip, lumbar, inguinal and/or pelvic pain. In patients with fatigue fractures, insidious lumbar, hip or pelvic pain may be present. Fatigue fractures of sacrum are typically related to repeated aggressive physical activity. Patients describe a recent increase in training intensity. In physical examination, lumbar range of motion is usually limited. Patient may display discomfort with palpation on sacrum. Provocative maneuvers of the joint may be painful aswell, yet it is not a specific finding for sacral fractures or SIJ syndrome. Rarely, patients may display positive dural tension tests due to lumbosacral nerve root or qaudaequina compression. However, neurologic examination is normal in most cases. Slow antalgic gait is typical for patients with sacral fractures. (44).

Roentgenography, bone scan, CT and MRI can be helpful in diagnosing sacral stress fractures. Roentgenography is usually the first

radiologic examination. Though it may seem insufficient to diagnose sacral stress fracture, it is useful to rule out other common pathologies such as lumbar spine pathologies. The most sensitive method to diagnose fracture is technetium-99m medronate (methylene diphosphonate - MDP) bone scan. Unfortunately, this test is not specific (45). CT visualizes bone tissue the best and it can be useful to confirm and complete a positive bone scan. Sometimes, MRI can be the first option due to its high sensitivity and specificity. Fat suppressed and STIR sequenced MRI play an important role in identifying bone marrow edema in acute fractures.

Medical treatment is an option for sacral fractures. Supplementation with calcium and vitamin D is indicated for sacral stress fractures. Furthermore, bisphosphonates and calcitonin can be used in case of an insufficiency type of stress fracture. Bisphosphonates, because of their side effects, are contraindicated for women who are at their childbearing period. They can be used only if there are osteopenia or osteoporosis accompanying a sacral stress fracture. Oral contraceptives must be used in female athletes with female athlete triad in order to regulate menstruation. Pain management strategies must be applied for patients with sacral stress fractures. Some patients may benefit from oral medication and from physical therapy methods such as heat application, gentle massage and electrical stimulation therapies.

In addition, sacroplasty is another novel and useful technique. Sacroplasty is similar to vertebroplasty. It is done in guidance of CT. Cement is injected in sacrum and sacral fracture instead of vertebra. Especially in case of fatigue type fractures, activity modification and cessation of the uncomfortable activity is important. Applying relative resting period (4-6 weeks) is very helpful for the patient. This helps avoid progression of the pathology and promote healing of the fracture (46-49). Sometimes a period as long as 12 months must pass in order for the sacral

insufficiency symptoms to dissolve. In cases of dramatic worsening of life quality and functional capacity, sacroplasty is a treatment option. It also removes the potential risks related to long lasting bed rest. Early mobilization is not contraindicated for patients with sacral insufficiency. Moderate weight bearing exercises must be encouraged as much as the patient can tolerate. Early mobilization may diminish complication rates. In the beginning of mobilization, devices like rolling walkers can be helpful. This is especially important because consequences of a fall can be devastating. In addition, hydrotherapy should be considered as a treatment modality to be applied while evaluating patient's mobilization in case of pain during weight bearing (49).

2.8 Spinal Deformities in Athletes

Spinal deformities are pretty common among general population. Yet, effects of spinal deformities on athletes and clinical progression are different from normal population. During sportive activities, excessive forces on the spine create potential risks for athletes with previous injury, history of operative or non-operative treatment.

There are parameters that determine sportive limitation and return to sports. Some of them are: Age of the patient, location of the deformity and type of sports involved in. During spinal maturation, vertebra develops with horizontal and vertical growth combinations. In the first decade of life, posterior endplates close. However, endplates at the vertebral body keep growing until adolescence. Significantly during adolescent grown spurt, thoracic kyphosis and lumbar lordosis becomes more prominent. Excessive training during this period may effect spinal development. For example, hyperlordosis can be seen in gymnasts and hyperkyphosiscan be seen in swimmers.

Adolescent idiopathic scoliosis incidence is between 2% and 3%. The incidence is necessarily higher in females. It is one of the most common deformities of childhood and adolescence. Incidence rates change in various sportive activities. Among premenarchal dancers, a relation was identified between body mass index and excessive training. It is known that immature bone is more sensitive to rhythmic loading forces, than mature bone. Thus among young dancers, a raise of 24% in minor spinal curvature disorders has been reported. Intense training before puberty may also lead to skeletal system deformities. It has been reported that scoliosis incidence is 10 times more especially in rhythmic gymnasts compared to normal population. The reason for this was identified to be the asymmetrical and repetitive forces effecting vertebral endplates in prepubertal and pubertal athletes. Certain activities like; swimming, throwing and serving in volleyball creates asymmetrical torque on vertebra and may lead to spinal curvature deformities. Thoracic curvature incidence up to 80% has been reported in professional athletes throwing with one hand.

Scoliosis

Adolescent idiopathic scoliosis is clinically asymptomatic. However, in some adolescents it may cause lower back pain to an extent. Leg lengths must be measures to rule out discrepancy. Physical examination of the spine must be done while the patient bends forward with knees extended and upper limbs hanging (Adam's test). Presence of a thoracic hump is in favor of a scoliosis. Possible kyphotic deformities should also be noted. Evaluation of curvatures with orthoroentgenography must be done with Cobb's method. It should be done from C7 to iliac crests. In curvature deformities above 20 degrees, whole spinal MRI is necessary to rule out any intraspinal pathology. During treatment and follow-ups, type of deformity must be identified and its progression risk should be determined.

Patient's age, gender and pubertal state are important parameters to determine growth potential. Thus, those are some of the parameters that give an idea of the risk of progression. Paraspinal muscle asymmetry in patients with scoliosis can be resolved with specific exercise programs. Rotational core condition exercises have positive effects on spinal curvature deformities. Core muscle strengthening and proper core exercises with proper assistance, improve body balance and enhance muscle coordination. Although patients with scoliosis are encouraged to do certain exercises, physical therapy just by itself is not enough to avoid progression. However, it should be kept in mind that these exercises improve flexibility and maintain physical endurance in athletes. Recent studies suggestthat scoliosis itself is not a contraindication for most sports. In addition to this, some authors claim that competitive swimming, professional volleyball and particular other sportive activities contribute progression. In contrast, some authors report that sportive activities in water improve flexibility and decrease compressive shearing forces on spine. Athlete may be involved in sportive activities during the period of time with their brace unmounted however it should be kept in mind that efficacy of wearing brace is dose-related. The ideal brace wearing time is between 18 to 23 hours per day. Activities such as cycling, horse riding, cheerleading etc. should be done with brace mounted. Recent studies suggest, encouraging athletes to joining sportive activities and using brace during sportive activities. New low profile braces are compatible with many sportive activities and provide sufficient comfort. Such braces are necessary not just for physical performance. They also help maintain a healthy psychosocial state. During treatment and follow-ups, contact sports and intense training should be avoided. In case of advanced scoliosis, operative treatment may be necessary. Sportive activities such as gymnastics, diving or ballet had been avoided after fusion operations in scoliosis surgery. However, rigid fixation of implants with new correction

and fixation methods made early return to sports possible. Return to sportive activities such as recreational swimming, cycling or hiking is possible after 2 months postoperatively. Sportive activities like tennis, basketball (without contact), or catching sports (e.g. catching a ball) can be done after 4 months postoperatively. In postoperative month 6, fusion must be seen. Return to contact sports is allowed if implants are stable and the patient is asymptomatic (50-53) (Figure 2,3).

Thoracic Kyphosis (Scheuermann's kyphosis)

Thoracic kyphosis is a rigid spinal kyphosis deformity, affecting the middle-thoracic and thoracolumbar region. Etiology is unclear however; genetic tendency is thought to be present. Hormonal disruptions, collagen defects, juvenile osteoporosis, vitamin deficiencies and repeated microtrauma on spine are some of the risk factors for thoracic kyphosis. Scheuermann's kyphosis is the most common reason for back pain among adolescent population. Most adolescents are asymptomatic at the beginning. First finding may be weak posture and a humped back. Vague pain at intrascpular region can be a reason for appointment. Pain aggravates with; heavy physical activity, being in extended sitting position and bending forward while standing. Back pain may continue for weeks until progressive kyphosis develops. Complaints of back pain becomes more often as apex of kyphosis gets closer to lumbar region. Scheuermann's kyphosis must come to mind when an adolescent with chronic or recurrent back pain comes to clinic. This pathology differentiates from adolescent's postural deformity by being a rigid deformity. In postural kyphosis, hump deformity disappears when the athlete is in prone position. In addition to this, decreased flexibility of hamstrings and compensatory increase in lumbar lordosis is present in patients with Scheuermann's kyphosis.

Radiologic findings can be listed as: Mora than 45 degrees of thoracic kyphosis, more than 5 degrees of anterior wedging at 3 adjacent vertebrae located at the apex of the kyphosis, disruption of vertebral apophysis ridging, narrowing in discs and schmorl nodules.

Incidence of kyphosis is higher in athletes engaged in physical activities, which cause asymmetrical loading. Solomon et al. showed that young dancers develop kyphosis due to certain exercises. One of these exercises is balancing the trunk above pelvis. In athletes who began wakeboarding earlier than 6 years of age showed increased incidence ratio of Scheuermann kyphosis. An atypic kyphosis serial has been published identifying higher rates of kyphosis at thoracolumbar junction zone in gymnasts who began sports earlier than 5 years of age.

On follow up, therapeutic exercises and core exercises should be recommended for all athletes. These exercises help increase elasticity of hamstring muscles, lumbodorsal muscles and lumbodorsal fascia. Further detailed treatment should be customized according to degree of kyphosis. Athletes with less than 50 degrees of kyphosis and immature skeleton should be periodically examined and radiographic evaluations should be made. Rehabilitation exercises should be applied in these patients until skeletal maturity is reached. Treatment with orthopedic brace should be considered in skeletally immature athletes who have more than 50 degrees of kyphosis angle. Operative treatment should be considered for patients with more than 70 degrees of kyphosis angle, persistent pain and progressive kyphosis. Asymptomatic athletes with less than 50 degrees of kyphosis angle may return to sports without any limitations while attending rehabilitation programs. Athletes who are being treated with orthopedic brace should be encouraged to return to sportive activities as much as possible. Athletes who are unable to attend sportive activities with a brace should return to sports after completion of treatment with brace. There are

precautions for athletes who are surgically treated with instrumentation extending to the lumbar region. These athletes should avoid sportive activities causing lumbar loading and body rotation like wrestling or weightlifting for 6 months. They can return to sportive activities after evaluation of fusion (54-59) (Figure 4,5).

References

1. McCarroll JR, Miller JM, Ritter MA. Lumbar spondylolysis and spondylolisthesis in college football players. A prospective study. Am J Sports Med. 1986 Sep-Oct;14(5):404-6.

2. Burgmeier RJ, Hsu WK. Spine surgery in athletes with low back pain-considerations for management and treatment. Asian J Sports Med. 2014 Dec;5(4):e24284.

3. Baker RJ, Patel D. Lower back pain in the athlete: common conditions and treatment. Prim Care. 2005 Mar;32(1):201-29.
4. Mortazavi J, Zebardast J, Mirzashahi B. Low Back Pain in Athletes. Asian J Sports Med. 2015 Jun;6(2):e24718.

5. Greydanus DE, Patel DR. Back pain in the adolescent athlete. Asian J Paediatr Pract. 2000 Jan;3(4):83–94.

6. Green JP, Grenier SG, McGill SM. Low-back stiffness is altered with warm-up and bench rest: implications for athletes. Med Sci Sports Exerc. 2002 Jul;34(7):1076-81.

7. Nadler SF, Malanga GA, DePrince M, Stitik TP, Feinberg JH. The relationship between lower extremity injury, low back pain, and hip muscle strength in male and female collegiate athletes. Clin J Sport Med. 2000 Apr;10(2):89-97.

8. Trainor TJ, Wiesel SW. Epidemiology of back pain in the athlete. Clin Sports Med. 2002 Jan;21(1):93-103.

9. Mosley GE, Evashwick-Rogler TW, Lai A, Iatridis JC. Looking beyond the intervertebral disc: the need for behavioral assays in

models of discogenic pain. Ann N Y Acad Sci. 2017 12;1409(1):51-66.

10. Adams MA. Biomechanics of back pain. Acupunct Med. 2004 Dec;22(4):178-88.

11. Yılmaz B, Alıcıoglu B, Kömür BH, Çiftdemir M, Özcan M, Çopuroglu C,Yalnız E. Long-term Changes in L5-S1 Disks Under the Fusion Region and the Effect of Sagittal Balance on Degeneration. Neurosurgery Quarterly. 2016;26(2):141-147.

12. Geraci Jr MC, Brown W, Velasquez JR. Low Back Pain in Adolescent Athletes: Diagnosis, Rehabilitation, and Prevention. Athl Ther Today. 2005 Sep;10(5):6-16.

13. Creighton DW, Shrier I, Shultz R, Meeuwisse WH, Matheson GO. Return-to-play in sport: a decision-based model. Clin J Sport Med. 2010 Sep;20(5):379-85.

14. Gera A, Pereira PC, Eapen C. Low back pain in adolescent athletes; evaluation and rehabilitation. J ExercSciPhysiother. 2015 Dec;11(2):76

15. Petering RC, Webb C. Treatment options for low back pain in athletes. Sports Health. 2011 Nov;3(6):550-5.

16. Alıcıoglu B, Yılmaz B, Bulakbası N, Çopuroglu C, Yalnız E, Aykaç B, Urut DU. Magnetic resonance imaging predictors of surgical outcome in degenerative lumbar spinal stenosis. Jpn J Radiol. 2012 Dec;30(10):811-8

17. Postacchini F, Postacchini R. Operative management of lumbar disc herniation. In: Advances in Minimally Invasive Surgery and Therapy for Spine and Nerves. Springer; 2011. p. 17–21.

18. Cordover AM, Cordover JB, Fleisig GS, Raszewski JA. Lumbar Disc Herniation in the Adolescent Athlete. In: Spinal Conditions in the Athlete. Springer; 2020. p. 215–34.

19. Ricciardi L, Chaichana KL, Cardia A, Stifano V, Rossini Z, Olivi A, et al. The exoscope in neurosurgery: an innovative "point of view". A systematic review of the technical, surgical and educational aspects. World Neurosurg. Doi:10.1016/j.wneu. 2018.12.202.

20. Davis EP, Showery JE, Prasarn ML, Dodwad S-NM. Traumatic Lumbar Injuries in Athletes. In: Spinal Conditions in the Athlete. Springer; 2020. p. 249–62.

21. Tezuka F, Sairyo K, Sakai T, Dezawa A. Etiology of Adult-onset Stress Fracture in the Lumbar Spine. Clin Spine Surg. 2017;30(3):E233-E238.

22. Lopez AJ, Scheer JK, Smith ZA, Dahdaleh NS. Management of flexion distraction injuries to the thoracolumbar spine. J ClinNeurosci. 2015 Dec;22(12):1853-6.

23. Cook RW, Hsu WK. Return to Play After Lumbar Spine Surgery. Clin Sports Med. 2016 Oct;35(4):609-19.

24. Rosenthal BD, Boody BS, Hsu WK. Return to Play for Athletes. NeurosurgClin N Am. 2017 Jan;28(1):163-71.

25. Wang TY, Mehta V, Berry-Candelario J, Karikari IO, Isaacs RE. Lumbar Spondylolisthesis. In: Minimally Invasive Spine Surgery. Springer; 2019. p. 429–37.

26. Syrmou E, Tsitsopoulos PP, Marinopoulos D, Tsonidis C, Anagnostopoulos I, Tsitsopoulos PD. Spondylolysis: a review and reappraisal. Hippokratia. 2010 Jan;14(1):17-21.

27. Khan SA, Sattar A, Khanzada U, Adel H, Adil SO, Hussain M. Facture of the Pars Interarticularis with or without Spondylolisthesis in an Adult Population in a Developing Country: Evaluation by Multidetector Computed Tomography. Asian Spine J. 2017 Jun;11(3):437-43.

28. Sairyo K, Sakai T, Takata Y, Yamashita K, Tezuka F, Manabe H. Spondylolysis and Spondylolisthesis in Athletes. In: Spinal Conditions in the Athlete. Springer; 2020. p. 235–47.

29. Stinson JT. Spondylolysis and spondylolisthesis in the athlete. Clin Sports Med. 1993 Jul;12(3):517-28.

30. Tekmyster G, Barbaria V, Lee CJ. Diagnosis and Treatment of Spondylolysis in the Adolescent Athlete. Conn Med. 2019 Oct;83(9):459-64.

31. Eck JC, Riley LH. Return to play after lumbar spine conditions and surgeries. Clin Sports Med. 2004 Jul;23(3):367-79.

32. Rashbaum RF, Ohnmeiss DD, Lindley EM, Kitchel SH, Patel VV. Sacroiliac Joint Pain and Its Treatment. Clin Spine Surg. 2016 Mar;29(2):42-8.

33. Polsunas PJ, Sowa G, Fritz JM, Gentili A, Morone NE, Raja SN, et al. Deconstructing Chronic Low Back Pain in the Older Adult-Step by Step Evidence and Expert-Based Recommendations for Evaluation and Treatment: Part X: Sacroiliac Joint Syndrome. Pain Med. 2016 Sep;17(9):1638-47.

34. Zelle BA, Gruen GS, Brown S, George S. Sacroiliac joint dysfunction: evaluation and management. Clin J Pain. 2005 Sep-Oct;21(5):446-55.

35. Butcher JD. Cross-country ski injuries. In: O'Connor F, Casa D, Davis B, et al. editors. ACSM's Sports Medicine: A Comprehensive Review. 1st ed. Philadelphia (PA): Wolters Kluwer Lippincott Williams and Wilkins; 2013. p. 598.

36. Foley BS, Buschbacher RM. Sacroiliac joint pain: anatomy, biomechanics, diagnosis, and treatment. Am J Phys Med Rehabil. 2006 Dec;85(12):997-1006.

37. Prather H. Sacroiliac joint pain: practical management. Clin J Sport Med. 2003 Jul;13(4):252-5.

38. Slobodin G, Rimar D, Boulman N, Kaly L, Rozenbaum M, Rosner I, et al. Acute sacroiliitis. ClinRheumatol. 2016 Apr;35(4):851-6.

39. Denis F, Davis S, Comfort T. Sacral fractures: an important problem. Retrospective analysis of 236 cases. ClinOrthopRelat Res. 1988 Feb;227:67-81.

40. Major NM, Helms CA. Sacral stress fractures in long-distance runners. AJR Am J Roentgenol. 2000 Mar;174(3):727-9.

41. Volpin G, Milgrom C, Goldsher D, Stein H. Stress fractures of the sacrum following strenuous activity. ClinOrthopRelat Res. 1989 Jun (243):184-8.

42. Boden BP, Osbahr DC. High-risk stress fractures: evaluation and treatment. J Am AcadOrthop Surg. 2000 Nov-Dec;8(6):344-53.

43. Lin JT, Lutz GE. Postpartum sacral fracture presenting as lumbar radiculopathy: a case report. Arch Phys Med Rehabil. 2004 Aug;85(8):1358-61.

44. Balseiro J, Brower AC, Ziessman HA. Scintigraphic diagnosis of sacral fractures. AJR Am J Roentgenol. 1987 Jan;148(1):111-3.

45. Reginster JY, Colson F, Morlock G, Combe B, Ethgen D, Geusens P. Evaluation of the efficacy and safety of oral tiludronate in Paget's disease of bone. A double-blind, multiple-dosage, placebo-controlled study. Arthritis Rheum. 1992 Aug;35(8):967-74.

46. Gerstenfeld LC, Thiede M, Seibert K, Mielke C, Phippard D, Svagr B, et al. Differential inhibition of fracture healing by non-selective and cyclooxygenase-2 selective non-steroidal anti-inflammatory drugs. J Orthop Res. 2003 Jul;21(4):670-5.

47. Boden BP, Osbahr DC, Jimenez C. Low-risk stress fractures. Am J Sports Med. 2001 Jan-Feb;29(1):100-11.

48. Lin J, Lachmann E, Nagler W. Sacral insufficiency fractures: a report of two cases and a review of the literature. J Womens Health Gend Based Med. 2001 Sep;10(7):699-705.

49. Garant M. Sacroplasty: a new treatment for sacral insufficiency fracture. J Vasc Interv Radiol. 2002 Dec;13(12):1265-7.

50. Stokes IAF, Spence H, Aronsson DD, Kilmer N. Mechanical Modulation of Vertebral Body Growth. Spine. 1996;21(10):1162–7.

51. Wojtys EM, Ashton-Miller JA, Huston LJ, Moga PJ. The association between athletic training time and the sagittal curvature of the immature spine. Am J Sports Med. 2000 Jul-Aug;28(4):490-8.

52. Warren MP, Brooks-Gunn J, Hamilton LH, Warren LF, Hamilton WG. Scoliosis and fractures in young ballet dancers. Relation to delayed menarche and secondary amenorrhea. N Engl J Med. 1986 May 22;314(21):1348-53.

53. Balioglu MB, Aydin C, Kargin D, Albayrak A, Atici Y, Tas SK, Kaygusuz MA. Vitamin-D measurement in patients with adolescent idiopathic scoliosis. Journal of Pediatric Orthopaedics 2017; 26 (1):28-52.

54. Swärd L. The thoracolumbar spine in young elite athletes. Current concepts on the effects of physical training. Sports Med. 1992 May;13(5):357-64.

55. Warren MP. The effects of exercise on pubertal progression and reproductive function in girls. J ClinEndocrinolMetab. 1980 Nov;51(5):1150-7.

56. Lindholm C, Hagenfeldt K, Ringertz BM. Pubertal development in elite juvenile gymnasts. Effects of physical training. Acta Obstet Gynecol Scand. 1994 Mar;73(3):269-73.

57. Wood KB. Spinal deformity in the adolescent athlete. Clin Sports Med. 2002 Jan;21(1):77-92.

58. Albayrak A, Balioglu MB, Mısır A, Kargın D, Tacal MT, Kaygusuz MA (2016). Preoperative and Postoperative Photographs and Surgical Outcomes of Patients with Kyphosis. Spine (Phila Pa 1976), 41 (19), E1185-1190.

59. Solomon R, Brown T, Gerbino PG, Micheli LJ. The young dancer. Clin Sports Med. 2000 Oct;19(4):717-39.

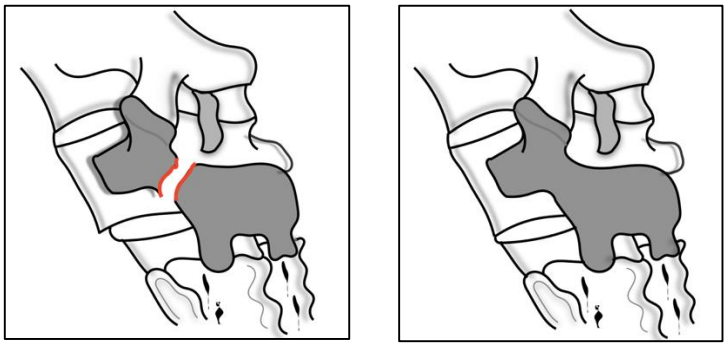

Figure 1. Illustration “Scottie dog sign” seen in Spondylolisthesis.

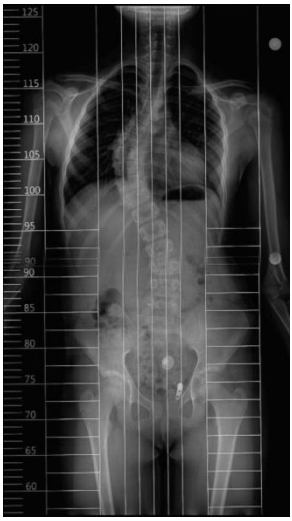

Figure 2. Orthoroentgenogram for scoliosis

Figure 3. Scoliosis

Figure 4. Orthoroentgenogram: Thoracic kyphosis

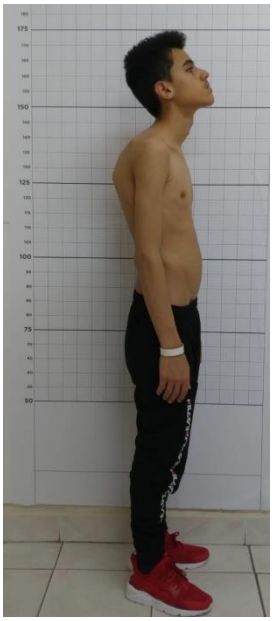

Figure 5. Body position in x-ray exam (orthoroentgenogram) for thoracic kyphosis

IV. REHABILITATION PROCESS AND PSYCHOLOGY IN ATHLETES

1.REHABILITATION PROCESS IN ATHLETES

Sinem Altın Demirbağ

Occupational Therapist

Evrim Şirin, MD, Assist.Prof.

Marmara University Hospital, Department of Orthopaedic Surgery and Traumatology, Istanbul-Turkey

İlknur Aktaş, MD, Prof

University of Health Sciences, Fatih Sultan Mehmet Training and Research Hospital, Department of Orthopaedic Surgery and Traumatology, Istanbul-Turkey

1.1. Role of physiotherapy and rehabilitation in sports injuries

Sportive activities are opportunity fields worldwide, for individuals to demonstrate their power and success. Various competitions are being organized in order to embody the success and become better. Athletes' bodies are trained intensely in a well-disciplined manner. This is done with a multi-disciplinary approach by certain assistant teams' programs and observations. Among this assistant team, rehabilitation crew has significant responsibilities. They take action in case of an injury this process. Health care professional should be well educated about topics such as human anatomy, physiology, kinesiology and biomechanics. They should be decent in teaching how to exercise and well informed about rehabilitation of an athlete. These professionals benefit from their knowledge in various fields in order to enhance athlete's performance and

health status. Strategies to avoid injuries and protective rehabilitation are of particular importance. Supporting an athlete's performance according to their physical attributes is significant to maintain their physical function and aid recovery. Rehabilitation after sports injuries is also of exceptional importance. Special treatment and rehabilitation is necessary after sports injuries to for the athlete's recovery. These are evidence-based interventions designed for athletes to regain their functionality. Rehabilitation begins immediately after sports injury. Rehabilitation program is designed specifically according to athlete after thorough examinations. The objective of a rehabilitation program is maximal functional recovery. Rehabilitation after injury and return to sports is a period that progresses in the best favor of the athlete according to type of injury and medical condition of the athlete. A common mistake is return of the athlete to sportive activities before completion of treatment. This leads to various problems such as recurrence of sports injuries. Thus, careful timing is necessary in decision of an athlete to return to sports. Consultation to a specialist is crucial while deciding on return to sports (1-5).

1.2. **Occupational therapy in sports injuries**

Occupational therapist is defined as an individual based health profession, which improves health and prosperity by meaningful and purposeful activities. Basic objective is to improve participation in daily activities. Occupational therapist work with individuals of every age. Their aim is to provide people independent, productive and satisfying life. They consider every need of the patient in order to provide a prosperous life to the patient. They improve abilities of individuals by organizing the activity or the environment in order to increase involvement in daily activities. Ergotherapists work to improve present good conditions of individuals and try to help them adapt to life. Occupational therapy is an individual-based

profession with a totalitarian approach focused on improving activity participation while supporting the patient psychologically, physically, cognitively, emotionally and sensationally. Occupational therapy is a health discipline. They have the important qualities, psychological and social abilities, medical knowledge and behavioral education in order to work with individuals, groups or populations. Following this definition, occupational therapy deals with any activity that is important or purposeful to an individual. Sportive activities are very important and meaningful for athletes. Sportive activities involve well-known mechanical and psychological risks. Injury during a sportive activity or poor health condition effects an athlete's handling capacity and participation in sportive activities. Decrease in activity performance leads to certain physical and psychological problems. An athlete devoid of sportive activity physically and mentally deteriorates. This may be due to various reasons such as an injury or a health condition. This whole situation leads the athlete to face different problems in various fields such as family life, social life and some other certain roles in life. Occupational therapist work on strategies to avoid problems after sportive injuries and organize rehabilitation of an athlete's current status (6).

References:

1.Dinc E, Kilinc BE, Bulat M, Erten YT, Bayraktar B. J. Effects of special exercise programs on functional movement screen scores and injury prevention in preprofessional young football players.Exerc Rehabil. 2017 Oct 30;13(5):535-540.

2.Erten YT, Dinc E, Kilinc BE, Sahinkaya T, Bayraktar B, KurtogluM. The Effects of Compression Garments and Electrostimulation On Athletes' Muscle Soreness and Recovery. J Exerc Rehabil. 2016;31:12(4):308-13

3.Grant, M. E., Steffen, K., Glasgow, P., Phillips, N., Booth, L., & Galligan, M. The role of sports physiotherapy at the London 2012 Olympic Games. British journal of sports medicine, 48(1), 63–70.

4.Lifshitz L. A sport physiotherapist as medical director: taking a leadership role. The Journal of orthopaedic and sports physical therapy, 42(9), 748–749.

5.Dhillon, H., Dhillon, S., Dhillon, M. S. Current Concepts in Sports Injury Rehabilitation. Indian journal of orthopaedics, 51(5), 529–536.

6.Hammond A. What is the role of the occupational therapist?. Best practice & research. Clinical rheumatology, 18(4), 491–505.

2.PSYCHOLOGY IN ATHLETES

Firdes Sonnur Yılmaz, MD

University of Health Sciences, Ümraniye Training and Research Hospital, Department of Psychology, Istanbul-Turkey

2.1. Psychological reactions in exercise and sports injuries

During the disability period, identity, anxiety, fear, lack of confidence, and loss of performance-related psychological reactions may arise in athletes.Sense of isolation, disappointment, anxiety, and depression are the most commonly encountered emotional states in athletes during the disability period. Indeed, you cannot prevent an injury 100% no matter how many measures you take. As its nature, sports will always involve injuries. First of all, athletes should be aware of this. Because the researches have shown that the first reactions to injuries are similar to the reactions to death and grief. People gradually gave denial, anger, bargaining, depression, and acceptance/reorganization reactions. These stages vary from athlete to athlete; in other words, it does not mean that every person will experience every stage. More generally, it can be said that athletes go through following emotional processes after injuries:

- Period of processing information about the injury: Athletes question to understand the condition and access real and relevant information about the situation.
- Emotional change and reactive behavior: Athletes go through emotional changes such as nervousness, confusion, exhaustion, lack of confidence, denial, and self-pity after recognizing the situation.

- Positive perspective and coping: Once athletes accept the injury, they will show an optimistic attitude and positive effort, thus allow the treatment process to continue more efficiently.

Certain reactions for disability are defined as poor adaptation indicators that unfavorably alter the course of disability, which are being angry and confused, obsessively questioning when to return to sports, deny, early return and re-injury, bragging about achievements, overrating the minor physical issues, feeling guilty, self-isolation, sudden mood changes and feeling desperate to recovery. It is noted that the athletes showing these symptoms should immediately receive sports psychologist support.Researches have shown that setting the healing as the target, positive self-talk, and using imagination for recovery enabled faster recovery after injury. These techniques contribute to the athlete's recovery process, emotional state during the recovery period, coping skills and gaining self-confidence. The factors affecting the delivery of normal performance of athletes after injury include the fear of re-injury, performance anxiety, feeling of inadequacy, and feeling worried about the performance (1,2).

2.2. How should psychology be in overcoming the injury?

The first step of overcoming a disability is to accept the disability. One of the common mistakes made by athletes today is trying to underestimate or directly ignore their disabilities. Hiding the details about an injury and trying to return to the activity quickly may lead to worsening of the disability and prolongation of the recovery period. Therefore, it is extremely important to accept disability and start treatment immediately. The most important step after this stage is to become organized. For this purpose, it is extremely important to consult a suitable physician for the identification of disability and recovery recommendations. An action plan based on actual dates from the first stage of the injury until the time to

return training should be developed. All the requirements for recovery should be known. Setting the date of each target will eliminate the unnecessary expectations during the time until returning to sports. During this period, receiving psychological support may become as important as receiving expert support for the disability, especially if the disability period prolongs. It should be noted that getting stressed about whether to return to sports and have the previous performance back is the most important factor to cause extra injury or re-injury. Motivation is also a key factor affecting the recovery period. Because motivation also increases commitment to treatment and directly promotes treatment. For this purpose, it is extremely important during the disability period to inform athletes about the disability from the beginning, explain the entire process, and provide support in setting feasible goals after the injury.

References:

1.Çopuroglu C, Yılmaz B, Yılmaz FS, Özcan M, Çiftdemir M, Çopuroglu E. Sexual dysfunction of male, after pelvic fracture. European Journal of Trauma and Emergency Surgery 2017;43(1), 59-63.

2.Hardy L, Jones G.Current issues and future directions for performance-related research in sport psychology.Journal of Sport Science 1994;12(1),61-98.