DENTISTRY CONCEPTS, RESEARCHES AND PRACTICE

Editor
Assoc. Prof. Dr. Melek Taşsöker

LIVRE DE LYON
2022

Dentistry

DENTISTRY CONCEPTS, RESEARCHES AND PRACTICE

Editor

Assoc. Prof. Dr. Melek Taşsöker

LIVRE DE LYON

Lyon 2022

DENTISTRY CONCEPTS, RESEARCHES AND PRACTICE

Editor

Assoc. Prof. Dr. Melek Taşsöker

LIVRE DE LYON

Lyon 2022

Dentistry Concepts, Researches and Practice

Editor •. Assoc. Prof. Dr. Melek Taşsöker
• Orcid: 0000-0003-2062-5713
Cover Design • Motion Graphics
Book Layout • Mirajul Kayal
First Published • December 2022, Lyon

ISBN: 978-2-38236-484-0

Publisher • Livre de Lyon
Address • 37 rue marietton, 69009, Lyon France
website • http://www.livredelyon.com
e-mail • livredelyon@gmail.com

LIVRE DE LYON

PREFACE

Primum non nocere

The principle of 'First do no harm!', dedicated to Hippocrates, is an ethical obligation imposed on physicians. A good physician is a person who serves his patient in line with ethical principles and carries out his profession with the responsibility of following scientific developments. The developments in digital image processing in the field of dental radiology bring great improvements in diagnostic dentistry applications, and the development of dental materials in the field of treatment.

In this book titled "Dentistry Concepts, Researches and Practice", there are five separate chapters, each of which is written by experts in the field, giving valuable information about the developments in the diagnosis and treatment concepts of dentistry. I hope this book will be useful to the world of science, dentists and dental students. I would like to thank all the valuable scientists and publishers who contributed to the creation of this book, which I am proud to be its editor.

Editor
Assoc. Prof. Dr. Melek TASSOKER, 2022
Necmettin Erbakan University Faculty of Dentistry
Department of Dentomaxillofacial Radiology Konya,
Turkey

CONTENTS

CHAPTER I

FRACTAL ANALYSIS IN DENTAL RADIOLOGY

Duygu Çelik Özen[1] & Şuayip Burak Duman[2]
[1]Research Assistant, Department of Oral and Maxillofacial Radiology, Faculty of Dentistry, Inonu University,
e-mail: duygu.celik@inonu.edu.tr
ORCID: 0000-0001-7274-3987

[2] Associate Prof. Department of Oral and Maxillofacial Radiology, Faculty of Dentistry, Inonu University,
e-mail: suayipburakduman@gmail.com

1. Fractal Concept

The shapes in classical Euclidean geometry (line, plane, circle, polygon, etc.) are often insufficient to understand and model objects with complex structures in nature. The famous mathematician Mandelbrot, in his work "The Fractal Geometry of Nature", used the term 'fractal' to denote objects whose complex geometry cannot be characterized by an integral dimension (1). Fractal is based on the Latin word 'fraktus' meaning 'broken, fractured'. The underlying principle of fractals is that a simple process that goes through an infinite number of iterations becomes a very complex one (2). The smallest part of a fractal shape has properties similar to the whole object. Formally, self-similarity is defined as a feature by which a subset is indistinguishable from the whole when enlarged to the size of the whole (3). An example

of this is the Koch curve model. The Koch Curve (KC) is a non-differentiable continuous curve, has infinite length and limits a finite area.(Figure 1)(4).

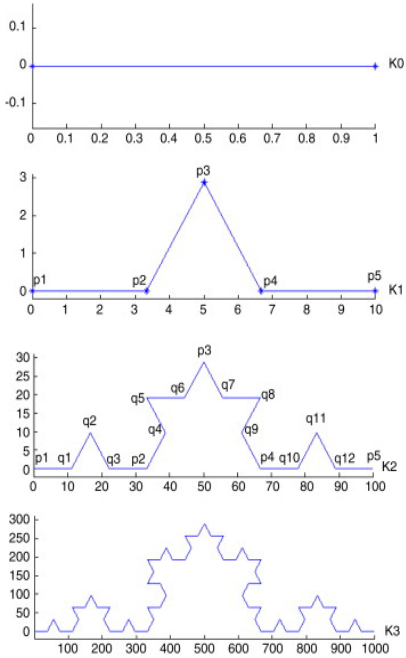

Figure 1: The middle third of the K0 curve is removed and replaced with two new pieces of the same length that will form an equilateral triangle. The resulting K1 curve, which consists of four equal parts, is called the generator of the Koch Curve. In the next step, the K2 curve is created by treating each of the four sections in the same way. This operation is performed infinitely and the Koch curve is seen as the figure obtained in the limit that we will denote with K∞.

2. Fractal Analysis and Fractal Dimension

The conversion of fractal analysis into a quantitative data is expressed as the fractal dimension (FD). Fractal dimension of an object; it

measures the object's complexity, space-filling capacity, or spatial extent (2). Fractal dimension values are expressed with fractional values between 0-3 instead of integers (5). In general, a high fractal dimension value indicates that the structure is more complex, and a low value indicates that the structure has a simpler internal order (6). The fractal dimension is a metric concept, not a topological one. With a more descriptive definition; If the Hausdorff dimension (Dh) of a cluster exceeds its topological dimension (DT), the cluster is considered to have fractal geometry (1). The topological dimension corresponds to the number of arguments required to define a cluster (7). For example, the topological dimension of a point is 0, While the topological dimension of the curves formed by the coming together of the points is 1, the topological dimension of the planes formed by the coming together of the curves is 2; It is generally accepted that the Euclidean space Rn is n-dimensional (8). The Hausdorff-Besicovitch dimension is determined by calculating the logarithmic ratio between the internal similarity(N)(homothety) of an object and the reciprocal(r) of this similarity ratio. In general terms, since an object with a fractal dimension D can be shrunk at the rate of $r = 1/\sqrt[D]{N}$ and divided into N pieces, the fractal dimension can be determined by the equation D=$\frac{\log(N)}{\log(1/\mathrm{r})}$. With this equation, the fractal dimension of a simple shape, such as the Sierpinski triangle, that is infinitely duplicated, can be calculated (Figure 2) (5).

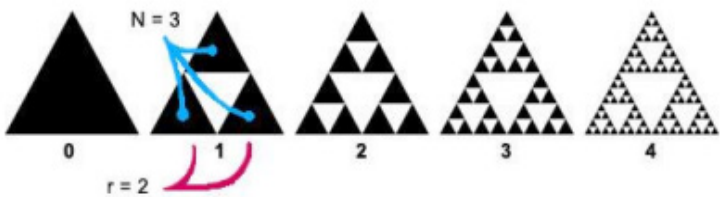

Figure 2: The midpoints of the equilateral triangle consisting of three equal sides of 1 unit are combined and 4 new equilateral

triangles with side lengths of ½ units are obtained. Then the middle triangle is subtracted. For 3 triangles with a side length of 1/2 unit in the figure no.1; $D=\frac{\log(3)}{\log(1/2)}=1.58$ For 9 triangles with side length 1/4 unit in figure no. 2; $D=\frac{\log(4)}{\log(1/9)}=1.58$. The same result is obtained at each step.

3. Fractal Dimension Calculation Methods:

There are many methods for fractal dimension calculation based on different theoretical foundations. Different methods can often result in different dimensions for the same feature. Although the algorithms applied differ, basically the quantile of the object is measured using various step sizes, the measured quantile and step dimensions are plotted on a logarithmic scale, and a regression line is determined in accordance with the obtained values. The slope of the regression line gives the fractal dimension of the structure (7). Lopes and Betrouni(7) fractal dimension calculation methods in the literature; box counting methods; fractional Brownian motion (fBm) methods and area measurement methods (Table 1).

Box-counting methods	Fractional Brownian motion (fBm) methods	Area measurement methods
Box-counting method (BC) Differential box-counting method (DBCM) “Extended counting” method (XCM)	Variogram method The power spectrum	Isarithm method (IM) Blanket method (BM) Triangular prism method (TPM)

Table 1: Fractal dimension computing methods

4. Application Areas for Fractal Analysis

The complexity of the investigated regions must be determined in several scientific disciplines. Fractal analysis, a quantitative technique for assessing intricate structures by looking at their basic elements; It has become increasingly popular in recent years for the analysis of biological images and is employed in many other research areas, including finance, architecture, geography, and astronomy. The complexity of the investigated regions must be determined in several scientific disciplines. Fractal analysis, a quantitative technique for assessing complex features by looking at their basic elements; It has become increasingly popular in recent years for the analysis of biological images and is employed in many other research areas, including finance, architecture, geography, and astronomy (9-12). Although there are studies in dentistry in which fractal analysis was performed using histological sections (13), the sounds made by patients with temporomandibular joint disorders during mouth opening (14) or dental materials (15), these analysis studies were mostly performed on radiological images. Fractal analysis studies on dental radiographs cover the evaluation of changes in the alveolar bone supporting the teeth in general, such as bone density measurement, implant stability and osseointegration, and the effects of some diseases on the jaw bones. Studies using fractal analysis on dental radiographs evaluate general changes in the alveolar bone that supports teeth, including bone density measurement, implant stability and osseointegration, and the effects of various disorders on the jaw bones.

5. Fractal Analysis in Dental Radiology

5.1. Fractal Analysis in Panoramic Radiographs

Since maxilla, mandible and all dentoalveolar structures are seen together in panoramic radiographs; both compact and trabecular bone can be evaluated and fractal analysis of multiple regions can

be performed by selecting regions of interest (ROI) from different regions. Spongy bone is metabolically more active than compact bone, therefore it gives more valuable diagnostic results as an indicator of metabolic activity. Microarchitecture of trabecular bone; It has fractal features such as complexity, self-similarity and characteristic length (16). Fractal analysis can be considered not only as a reflection of trabecular bone microarchitecture, but also as a noninvasive tool to measure changes in mineral content of alveolar bone (17). There is a positive correlation between fractal size and mineral density of the jaw bones, according to studies in which medullary bone trabeculation and changes in cortical bone in panoramic radiographs of patients with osteoporosis were evaluated by fractal analysis(18–20), though some found no statistically significant difference (21, 22).

There are also studies in which fractal analysis is used to determine the bone quality of recipient sites before implant placement on panoramic radiographs or to evaluate osseointegration after implant surgery (23, 24). Zeytinoğlu et al. performed fractal dimension analysis by determining three different areas of interest (ROI) on the periimplant alveolar bone in the 3rd month, 6th month and 12th month panoramic radiographs of patients who will be treated with fixed prosthesis on implant. As a result of this study, it was determined that the 6th month fractal values decreased significantly compared to the initial values, but there was no statistically significant difference between the 6th and 12th month fractal values(25). The fractal values of the trabecular bone surrounding the implant were compared on four panoramic radiographs taken from the patient before the implant and one week, one month, and two months after implant placement in a study investigating the effectiveness of the fractal analysis method in determining implant osseointegration. Fractal analysis is a noninvasive method that can be used in the evaluation of osseointegration. The conclusion was that it might be a method (26). Arsan et al.(27), on the other hand,

correlated low fractal dimension values with severe degenerative changes in bilateral mandibular condyle heads, as a result of fractal analysis analysis performed in patients with temporomandibular joint disorders. Creton et al.(28) concluded that there was no significant difference in radiographic parameters of mandibular trabecular bone structure in patients with and without hypodontia. Again, fractal analysis is used to evaluate the bone healing process after orthognathic surgery on panoramic radiographs(29), such as sickle cell anemia(17), chronic renal failure(30), renal osteodystrophy(31), Type 1 and Type 2 Diabetes Mellitus (32). There are studies evaluating the changes in the trabeculation of the jaw bones of individuals with systemic diseases and syndromes such as Osteogenesis Imperfecta (33).

5.2. Fractal Analysis on Periapical Radiographs

Periapical radiographs are an intraoral imaging technique that display the hard tissue in the interdental and periradicular regions as well as the whole size of the teeth from the crown to the root apex (34). Fractal analysis made with periapical radiographs are mostly used in the fields of endodontics and periodontology. In the field of periodontology; In a study in which fractal size was calculated on periapical radiographs of the area from the mandibular posterior regions of individuals with healthy gingiva and periodontitis, it was shown that fractal analysis was able to distinguish changes in the interdental trabecular bone pattern of patients with moderate periodontitis (35), while according to another study, gingivitis and periodontitis patients can be separated from each other by fractal size calculation on periapical radiographs (36). On the other hand, Updike et al. (16) compared the trabecular bone pattern of these patient groups by calculating fractal size using the box-counting method on the periapical radiographs of healthy, moderate and severe periodontitis patients. This study found that the differences between healthy people and those with periodontal disease may be

quantitatively detected using fractal analysis using the box-counting method (16).

In studies in the field of endodontics, fractal analysis has generally been used as a quantitative method for monitoring the healing of the periapical region after root canal treatment. Yu et al. (37) on the periapical radiographs of molar teeth with a radiolucent lesion larger than 2 mm in the periapical region taken before root canal treatment and 6 months after a successful root canal treatment; They calculated fractal size in 2 different ROIs of 128x128 pixels, with a pixel size of 0.02 mm. In another study, fractal size analysis on periapical radiographs was used to differentiate between patients with gingivitis and those with periodontitis. Huang et al. (38) compared the fractal size values they calculated and determined 8 different ROIs on the periapical radiographs taken before root canal treatment or apical surgery and 1 year after the osteolytic apical lesion procedure. They concluded that it can be determined. Amer et al. (39) investigated whether there is a correlation between these regions by performing fractal, area function and particle count analyzes in 6 ROIs (maxillary and mandibular anterior, premolar and molar tooth regions) on 600 periapical radiographs. According to this study, fractal analysis is a practical method for investigating trabecular bone architecture, and particle count and area function analyzes support fractal analysis in determining bone microstructure and bone mineral density.

5.3. Fractal Analysis on Bitewing Radiographs

By biting the bite wing on the specially prepared film onto the patient, bitewing radiographs are taken, and the central beam is then directed to move through the interproximal areas. While the crowns and some of the roots of the maxillary and mandibular teeth in the imaged area with Bitewing projections, caries, restoration or calculus in the interproximal area, the condition of the alveolar crest, and the pulp chambers of the teeth can be evaluated; these

radiographs do not allow for a complete view of the roots and apical area (34). Yaşar et al. (40) reported fractal analysis on bitewing radiographs to investigate at changes in alveolar bone under restoration in individuals with proximal overflow restoration but no visible vertical bone loss. When the fractal dimensions of the alveolar bone were evaluated in the study between 28 teeth with overhang restorations and those without contralateral restorations, no statistically significant difference was found. However, it was stated that protruding dental restorations seem to cause a decrease in trabecular bone density, and this may cause decreases in alveolar bone height in the following years. Another study employing Bitewing radiographs found that when performing fractal analysis on alveolar bone, ROIs of varied sizes and shapes may have an impact on the results (41).

5.4. Fractal Analysis with Cone Beam Computed Tomography (CBCT) Images

CBCT is a useful imaging method that produces submillimeter resolution images of diagnostic quality, enables volumetric imaging of osseous structures in the maxillofacial region, and provides more detailed diagnostic information when two-dimensional applications such as panoramic or conventional radiographs are insufficient (34). CBCT voxels are isotropic and thanks to this feature, measurements made in different planes give the same accurate result. In CBCT sagittal sections, Gümüşsoy et al. (42) found that erosive degenerative bone change in the mandibular condyle. They classified these images into three groups: normal, slightly erosive, and extremely erosive. They compared these groups after determining ROI on the coronal sections of condyles with degenerative bone change (DBC) and using the box-counting method, and they emphasized that there was a statistically significant difference between the FD values of patients with erosive DBC in the condyle and those without. Kaymazmaz et al. (43) performed fractal analysis to examine

trabecular changes in mandibular condyle heads on CBCT images of patients diagnosed with temporomandibular joint osteoarthritis (TMJOA) and to compare it with mandibular condyle trabeculation of healthy patients. It was emphasized that it can be used as an auxiliary method to provide early detection of TMJOA.

When using CBCT images to assess midpalatal suture maturity, Kwak et al. (44) looked into whether fractal analysis would be a determinant. By comparing fractal dimensions of midpalatal sutures, it was concluded that there is a strong relationship between fractal size and midpalatal suture maturation stage, therefore fractal analysis can be a useful method for the evaluation of midpalatal suture maturation (44). In this study, it was also predicted that the optimum fractal dimension threshold value could be determined and this value could be used as a reference for the non-surgical rapid maxillary enlargement procedure.

In a study in which CBCT images of patients with Medication-Related Osteonecrosis of the Jaw (MRONJ), which is seen as a side effect of some antiresorptive and antiangiogenic drugs, and who also have clinical osteonecrosis, were compared with CBCT images of healthy patients; it has been stated that fractal analysis can be used as a method of distinguishing between these two groups (45).

Although three-dimensional images are obtained with CBCT, many studies in the literature have been carried out on two (2D) sections of CBCT. Oliveira et al. (46) used fractal analysis to assess lesions of ossifying fibroma and fibrous dysplasia on 2D and 3D CBCT images. A significant difference was detected between the two lesion groups in all ROIs in panoramic reconstruction and axial sections created on 2D images, and fractal analysis results on 3D images gave similar results. In conclusion, it has been reported that fibrous dysplasia lesions show a more complex structure than ossifying fibromas.

5.5. Fractal Analysis with Ultrasound Images

Ultrasound is a technique that creates real-time images with sound waves without using ionizing radiation (34). In this imaging technique, ultrasound is generated and sent to the tissues, and the sound waves reflected from the tissue are detected and converted into electrical signals by the probes. In dentistry, it is generally used for soft tissue examinations such as salivary glands, lymph nodes and muscles in the head and neck region. There are fractal analysis studies on ultrasound images of salivary glands in the literature. Badea et al. (47) of a patient with acute pain and swelling in the left submandibular salivary gland; performed fractal analysis to compare submandibular salivary gland ultrasound images with the asymptomatic side. Ultrasound imaging of salivary glands was made using ARFI (acoustic radiation force impulse) and real-time elastography technique. According to the results of the study, the FD value of the left mandibular salivary gland with symptoms was calculated higher than the asymptomatic side, and this was interpreted as that images with a high FD could indicate the presence of pathology. Again, in a study evaluating the pathology in the salivary glands with FA; Ultrasound images of benign salivary gland tumors such as Warthin and Pleomorphic Adenoma and malignant salivary gland tumors were used. As a result of this study, it was reported that the FD values of Pleomorphic Adenoma were higher than those of Warthin and malignant tumors (48).

5.6. Fractal Analysis with Other Imaging Methods

In the literature, there are also studies in which fractal analysis with lateral cephalometric radiographs, sialography, hand-wrist radiographs and micro-CT, which is preferred in in vitro studies, are used in the field of dentistry. Otis et al. (49) examined the lateral cephalometric radiographs of 22 patients who received orthodontic treatment before and after treatment in order to evaluate whether the

apical resorption of the teeth is related to the shape and density of the surrounding alveolar bone. Tooth full size, root length, root area, alveolar area around the root, medullary bone areas were measured with an interactive software algorithm, and trabecular space area and fractal size were calculated by determining an ROI in the symphysis. In this study, while the size of the tooth and root was associated with the degree of root resorption, no significant correlation was observed between the amount of alveolar bone around the root, the thickness of the cortical bone, fractal measurements of the symphysis trabeculation, and apical resorption.

In a study that analyzed ductal patterns in sialograms with fractal size calculations, it was reported that the fractal values of parotids with Sjögren's syndrome and normal parotid fractal values were significantly different, and it was stated that fractal size could serve as a numerical rating of the progression of this disease (50). Akbulut et al. (51) investigated the distal, proximal and medial phalanges of the middle finger on the hand-wrist radiographs of successful and unsuccessful RPE groups to investigate whether fractal analysis on hand-wrist radiographs is a helpful method to predict the success of rapid palatal expansion (RPE). They compared the values of the two groups by calculating the fractal dimension in 4 different ROIs, at the epiphysis-diaphysis line of the radius bone. As a result of the finding that patients who underwent unsuccessful RPE treatment had higher fractal values, it was hypothesized that fractal analysis of hand-wrist radiographs would be useful in determining whether RPE will be effective.

In addition, there are different fractal analysis studies in the literature, differential studies were performed to evaluate the relationship between systemic bone turnover and the microstructure of alveolar bone using micro-CT (52), bone density measurement in dental implant recipient sites (53), and the effect of porous titanium granules and bone graft materials in patients who underwent maxillary sinus lift (54).

Conclusion

Since fractal analysis is noninvasive, simple to use, and can be used to objectively assess the complexity of structures on radiographs, its usage in dentistry has considerably expanded in recent years. Most of the research investigated in this study used the box-counting technique for fractal analysis, and statistically significant correlations were observed in the regions evaluated by fractal parameters in general.

References

1. Mandelbrot BB, Mandelbrot BB. The fractal geometry of nature: WH freeman New York; 1982.

2. Naik GR, Arjunan S, Kumar D. Applications of ICA and fractal dimension in sEMG signal processing for subtle movement analysis: a review. Australasian physical & engineering sciences in medicine. 2011;34(2):179-93.

3. Mandelbrot B. How long is the coast of Britain? Statistical self-similarity and fractional dimension. science. 1967;156(3775):636-8.

4. Ri S-I, Drakopoulos V, Nam S-M. Fractal interpolation using harmonic functions on the Koch curve. Fractal and Fractional. 2021;5(2):28.

5. Uyar A, Öztürk D. Fraktal analizin yeryüzü araştırmalarında kullanılması. Afyon Kocatepe Üniversitesi Fen ve Mühendislik Bilimleri Dergisi. 2017;17(4):147-55.

6. Güleç M, Taşsöker M, Şener S. Tıpta ve Diş Hekimliğinde Fraktal Analiz. Ege Üniversitesi Diş Hekimliği Fakültesi Dergisi. 2019;40(1):17-31.

7. Lopes R, Betrouni N. Fractal and multifractal analysis: a review. Medical image analysis. 2009;13(4):634-49.

8. Sánchez I, Uzcátegui G. Fractals in dentistry. Journal of dentistry. 2011;39(4):273-92.

9. Lawrence MJ, Sabra A, Thomas P, Obaid DR, D'Silva LA, Morris RH, et al. Fractal dimension: A novel clot microstructure biomarker use in ST elevation myocardial infarction patients. Atherosclerosis. 2015;240(2):402-7.

10. Zheng Y, Keller BM, Ray S, Wang Y, Conant EF, Gee JC, et al. Parenchymal texture analysis in digital mammography: A fully automated pipeline for breast cancer risk assessment. Medical physics. 2015;42(7):4149-60.

11. Tălu S. Multifractal characterisation of human retinal blood vessels. Oftalmologia (Bucharest, Romania: 1990). 2012;56(2):63-71.

12. Udhayakumar G, Sujatha C, Ramakrishnan S. Trabecular architecture analysis in femur radiographic images using fractals. Proceedings of the Institution of Mechanical Engineers, Part H: Journal of Engineering in Medicine. 2013;227(4):448-53.

13. Goutzanis L, Papadogeorgakis N, Pavlopoulos P, Katti K, Petsinis V, Plochoras I, et al. Nuclear fractal dimension as a prognostic factor in oral squamous cell carcinoma. Oral Oncology. 2008;44(4):345-53.

14. Badwal RS. The application of fractal dimension to temporomandibular joint sounds. Computers in biology and medicine. 1993;23(1):1-14.

15. Takuma Y, Shiraishi T, Fujita T, Hisatsune K. Tarnish resistance evaluation of experimental Pd-free Ag-Au-Pt-Cu dental alloys. Dental materials journal. 2010;29(3):330-5.

16. Updike SX, Nowzari H. Fractal analysis of dental radiographs to detect periodontitis-induced trabecular changes. Journal of periodontal research. 2008;43(6):658-64.

17. Demirbaş AK, Ergün S, Güneri P, Aktener BO, Boyacıoğlu H. Mandibular bone changes in sickle cell anemia: fractal analysis. Oral Surgery, Oral Medicine, Oral Pathology, Oral Radiology, and Endodontology. 2008;106(1):e41-e8.

18. Hwang JJ, Lee J-H, Han S-S, Kim YH, Jeong H-G, Choi YJ, et al. Strut analysis for osteoporosis detection model using

dental panoramic radiography. Dentomaxillofacial Radiology. 2017;46(7):20170006.

19. Kavitha MS, An S-Y, An C-H, Huh K-H, Yi W-J, Heo M-S, et al. Texture analysis of mandibular cortical bone on digital dental panoramic radiographs for the diagnosis of osteoporosis in Korean women. Oral surgery, oral medicine, oral pathology and oral radiology. 2015;119(3):346-56.

20. Law AN, Bollen A-M, Chen S-K. Detecting osteoporosis using dental radiographs: a comparison of four methods. The Journal of the American Dental Association. 1996;127(12):1734-42.

21. Tosoni GM, Lurie AG, Cowan AE, Burleson JA. Pixel intensity and fractal analyses: detecting osteoporosis in perimenopausal and postmenopausal women by using digital panoramic images. Oral Surgery, Oral Medicine, Oral Pathology, Oral Radiology, and Endodontology. 2006;102(2):235-41.

22. Yasar F, Akgunlu F. The differences in panoramic mandibular indices and fractal dimension between patients with and without spinal osteoporosis. Dentomaxillofacial radiology. 2006;35(1):1-9.

23. Sansare K, Singh D, Karjodkar F. Changes in the fractal dimension on pre-and post-implant panoramic radiographs. Oral Radiology. 2012;28(1):15-23.

24. Tözüm TF, Dursun E, Uysal S. Radiographic fractal and clinical resonance frequency analyses of posterior mandibular dental implants: their possible association with mandibular cortical index with 12-month follow-up. Implant dentistry. 2016;25(6):789-95.

25. Zeytinoğlu M, İlhan B, Dündar N, Boyacioğlu H. Fractal analysis for the assessment of trabecular peri-implant alveolar bone using panoramic radiographs. Clinical oral investigations. 2015;19(2):519-24.

26. Soylu E, Coşgunarslan A, Çelebi S, Soydan D, Demirbaş AE, Demir O. Fractal analysis as a useful predictor for determining

osseointegration of dental implant? A retrospective study. International Journal of Implant Dentistry. 2021;7(1):1-8.

27. Arsan B, Köse TE, Çene E, Özcan İ. Assessment of the trabecular structure of mandibular condyles in patients with temporomandibular disorders using fractal analysis. Oral surgery, oral medicine, oral pathology and oral radiology. 2017;123(3):382-91.

28. Créton M, Geraets W, Verhoeven JW, van der Stelt PF, Verhey H, Cune M. Radiographic features of mandibular trabecular bone structure in hypodontia. Clinical implant dentistry and related research. 2012;14(2):241-9.

29. Heo M-S, Park K-S, Lee S-S, Choi S-C, Koak J-Y, Heo S-J, et al. Fractal analysis of mandibular bony healing after orthognathic surgery. Oral Surgery, Oral Medicine, Oral Pathology, Oral Radiology, and Endodontology. 2002;94(6):763-7.

30. Gumussoy I, Miloglu O, Cankaya E, Bayrakdar IS. Fractal properties of the trabecular pattern of the mandible in chronic renal failure. Dentomaxillofacial Radiology. 2016;45(5):20150389.

31. Fernandes MA, Rosa EAR, Johann A, Gregio AMT, Trevilatto PC, Azevedo-Alanis LR. APPLICABILITY OF FRACTAL DIMENSION ANALYSIS IN DENTAL RADIOGRAPHS FOR THE EVALUATION OF RENAL OSTEODYSTROPHY. Fractals-Complex Geometry Patterns and Scaling in Nature and Society. 2016;24(1).

32. Kurşun-Çakmak E, Bayrak S. Comparison of fractal dimension analysis and panoramic-based radiomorphometric indices in the assessment of mandibular bone changes in patients with type 1 and type 2 diabetes mellitus. Oral Surg Oral Med Oral Pathol Oral Radiol. 2018;126(2):184-91.

33. Apolinário AC, Sindeaux R, de Souza Figueiredo PT, Guimarães AT, Acevedo AC, Castro LC, et al. Dental panoramic indices and fractal dimension measurements in

osteogenesis imperfecta children under pamidronate treatment. Dentomaxillofacial Radiology. 2016;45(4):20150400.

34. White SC, Pharoah MJ. White and Pharoah's Oral Radiology: Principles and Interpretation: Elsevier Health Sciences; 2018.

35. Sener E, Cinarcik S, Baksi BG. Use of Fractal Analysis for the Discrimination of Trabecular Changes Between Individuals With Healthy Gingiva or Moderate Periodontitis. Journal of periodontology. 2015;86(12):1364-9.

36. Shrout MK, Roberson B, Potter BJ, Mailhot JM, Hildebolt CF. A comparison of 2 patient populations using fractal analysis. Journal of periodontology. 1998;69(1):9-13.

37. Yu Y-Y, Chen H, Lin C-H, Chen C-M, Oviir T, Chen S-K, et al. Fractal dimension analysis of periapical reactive bone in response to root canal treatment. Oral Surgery, Oral Medicine, Oral Pathology, Oral Radiology, and Endodontology. 2009;107(2):283-8.

38. Huang C, Chen J, Chang Y, Jeng J, Chen C. A fractal dimensional approach to successful evaluation of apical healing. International endodontic journal. 2013;46(6):523-9.

39. Amer ME, Heo M-S, Brooks SL, Benavides E. Anatomical variations of trabecular bone structure in intraoral radiographs using fractal and particles count analyses. Imaging science in dentistry. 2012;42(1):5-12.

40. Yasar F, Yesilova E, Akgünlü F. Alveolar bone changes under overhanging restorations. Clinical oral investigations. 2010;14(5):543-9.

41. Shrout M, Hildebolt C, Potter B. The effect of varying the region of interest on calculations of fractal index. Dentomaxillofacial Radiology. 1997;26(5):295-8.

42. GÜMÜŞSOY İ, DUMAN ŞB, BAYRAKDAR İS, YAŞAY, ÇAKUR B. Correlations between fractal dimension of mandibular

condylar bone and Degenerative Joint Disease-A CBCT based analysis. 7tepe Klinik. 2019;15(3):328-33.

43. Kayipmaz S, Akçay S, Sezgin ÖS, Çandirli C. Trabecular structural changes in the mandibular condyle caused by degenerative osteoarthritis: a comparative study by cone-beam computed tomography imaging. Oral Radiology. 2019;35(1):51-8.

44. Kwak KH, Kim SS, Kim Y-I, Kim Y-D. Quantitative evaluation of midpalatal suture maturation via fractal analysis. The korean journal of orthodontics. 2016;46(5):323-30.

45. Bachtler R, Walter C, Schulze RK. Fractal dimension in CBCT images as predictor for MRONJ: a retrospective cohort study. Clinical oral investigations. 2021;25(4):2113-8.

46. de Oliveira CdNA, Barra SG, Abreu LG, Machado VC, Pinheiro JdJV, Henriques JAS, et al. Fractal analysis of fibrous dysplasia and ossifying fibroma in 2D and 3D CBCT images. Journal of Oral and Maxillofacial Surgery, Medicine, and Pathology. 2022.

47. Badea AF, Lupsor Platon M, Crisan M, Cattani C, Badea I, Pierro G, et al. Fractal analysis of elastographic images for automatic detection of diffuse diseases of salivary glands: Preliminary results. Computational and Mathematical Methods in Medicine. 2013;2013.

48. Chikui T, Tokumori K, Yoshiura K, Oobu K, Nakamura S, Nakamura K. Sonographic texture characterization of salivary gland tumors by fractal analyses. Ultrasound in medicine & biology. 2005;31(10):1297-304.

49. Otis LL, Hong JS-H, Tuncay OC. Bone structure effect on root resorption. Orthodontics & craniofacial research. 2004;7(3):165-77.

50. Honda E, Domon M, Sasaki T. A method for determination of fractal dimensions of sialographic images. Investigative Radiology. 1991;26(10):894-901.

51. Akbulut S, Bayrak S, Korkmaz YN. Prediction of rapid palatal expansion success via fractal analysis in hand-wrist

radiographs. American Journal of Orthodontics and Dentofacial Orthopedics. 2020;158(2):192-8.

52. Arisaka R, Matsuo A, Chiba H, Takahashi H, Takeuchi S, Watanabe M, et al. Preliminary clinical study to evaluate the relationship between systemic bone turnover and the microstructure of the alveolar bone. Oral Science International. 2009;6(1):27-35.

53. González-García R, Monje F. The reliability of cone-beam computed tomography to assess bone density at dental implant recipient sites: a histomorphometric analysis by micro-CT. Clinical oral implants research. 2013;24(8):871-9.

54. Dursun E, Dursun CK, Eratalay K, Orhan K, Celik HH, Tözüm TF. Do porous titanium granule grafts affect bone microarchitecture at augmented maxillary sinus sites? A pilot split-mouth human study. Implant dentistry. 2015;24(4):427-33.

CHAPTER II

ESTHETIC REMOVABLE DENTURES PART I: POLYAMIDE DENTURES

Kubra Degirmenci
(Assoc.Prof.Dr.) Bolu Abant Izzet Baysal University, Faculty of Dentistry, Department of Prosthodontics, Bolu, Turkey
e-mail:dtkubradegirmenci@outlook.com
ORCID:0000-0001-6429-4923

1. Introduction

With the developments in dentistry and increased health awareness of individuals, the incidence of complete edentulous has decreased, while partial edentulism has increased with the prolonged life expectancy in the elderly population.(1,2) It is estimated that approximately 50% of adults in the United States will lose one or more teeth, and that the number of individuals with partial edentulism will exceed 200 million in the next 15 years. (3) Therefore, it can be thought that the need for prosthetic treatment planning for partial edentulism will continue to increase in the future.

Implant supported prosthetic treatment for partial edentulous patients has become widespread today but removable partial denture treatment is also applied as a frequent treatment option. (3,4) Although dental implant treatment is a good option for partial edentulous patients, but financial limitations may cause patients to prefer other prosthetic treatments. In cases where implant treatment cannot be applied and there are not enough abutment teeth for

fixed prosthetic treatment, rehabilitation should be provided with removable partial dentures.(4,5) While it is aimed that removable partial dentures will restore the functions of missing teeth, it is also important to ensure aesthetics and harmony with oral tissues. The retention of traditional partial removable dentures is provided by clasps that are the continuity of the metal framework. The gray color of the metal from which the clasps are produced is not compatible with natural teeth and oral tissues. (6) Patients are uncomfortable with incompatible appearance of their dentures. Increasing in aesthetic awareness leds to prefer aesthetic thermoplastic resin materials such as polyamide materials. Some polyamide materials are listed in Table 1.

Table 1. Some Polyamide Materials Which Can Be Used For Removable Partial Dentures.

Product Name	Manufacturer
Valplast	UNIVAL
Lucitone FRS	DENTSPLY International
Ultimate	Ultimate
Deflex	Nuxen

2. Polyamide

Polyamide consists of aliphatic, cycloaliphatic, and aromatic fibers formed by polycondensation of polyamide adipic acid and hexamethyldiamine.(7,8) Polyamide is a naturally occurring or artificially prepared resin composed of diamine and dibasic acid monomers. (6,9) Polyamide is considered as a very good alternative to metal framework of removable partial dentures due to its durability, resistance to fracture, flow properties, and improved heat resistance. (6,10) The material properties of different polyamides under the same conditions may also be different each other. (11)

Various properties of different brands polyamide materials have been searched in various studies.

2.1. Valplast

Valplast is a type of polyamide resin composed of polylaurolactam (nylon 12, chemical formula {CO(OH2)11NH}n). (10)

Its elasticity was excellent to stand under maximum loads. It was reported that high thermal contraction could be seen in Valplast, therefore control follow-up appointments were required for patients with few natural teeth and Valplast could be proper for spare dentures. (10,12) Especially, Valplast can be convenient to rehabilate deficiency of one-two anterior teeth. The rigidity of Valplast can be strengthen by using a metal framework and it could be applied for multiple missing teeth cases. (13)

Valplast is semitransparent and it is in harmony with gums. However, discoloration effect of the spice was higher for Valplast compared with acrylic resin.(14)

2.2. Lucitone FRS

Lucitone FRS is a type of polyamide and its structure mades from a high grade microcrystalline, and Lucitone FRS shows excellent stability.(10) The absorbency of Lucitone FRS is higher than acrylic resin.(15) The color stability of Lucitone FRS is lower than acrylic resin after exposure to dyeing agents. (16)

The bond strength of Lucitone FRS to self-curing resins is not strength and mechanical retentive cavities are required to achieve connection with artifical teeth. (10) Therefore, Lucitone FRS without a metal framework can be considered for dentures replace a few missing teeth.

2.3. Ultimate

Ultimate is a novel soft polyamide material with lower flexural strength than Valplast and it can be produced as a thin base to

improve oral comfort of patients. Moreover, the repair of Lucitone FRS can be achieved with Ultimate. (10) The properties of Ultimate should be searched in further investigations.

2.4. Deflex

Deflex is another polyamide material and it can be molded with thermo-injection method to produce removable dentures. The toxicity feeature of deflex is comparable with acrylic resin used as denture base material. (17) Moreover, deflex was suggested as a base material for complete dentures but not appropriate for removable partial denture. (18)

It was reported that deflex showed higher flexibility than acrylic resin but hardness values of deflex were defined lower than acrylic resin in a former study. (19) Therefore, the effect of lower hardness nature of deflex on clinical success of dentures should be investigated.

3. Polyamide Dentures

Polyamide dentures can be preferred to handle the allergic reaction to metal and/or residual monomers of acrylic resin. (20) Additionally, patients feel better with polyamide dentures because it has a softer surface texture and lower elastic modulus compared with acrylic resin.(18) Polyamide dentures can be good alternatives instead of the hard plate of acrylic resin dentures for patients with systemic disease such as diabetes who have more sensitive oral tissues. (7) Further, since polyamide material can stay moist for a longer time compared to acrylic resin, they can improve to comfort of patients with xerostomia. (21) However, some important components such as occlusal rests and rigid framework are not found in polyamide dentures and the rigidity of dentures is lower than acrylic dentures. (13) Since polyamide is not as hard as acrylic, external factors can leave deeper marks on polyamide surface than the surface of

acrylic resin. (22) Therefore, color changes can occur more easily on the surface and carefully cleaning procedure should be applied to eliminate microorganisms. (15,23) It was reported that Candida albicans and Staphylococcus aureus microorganisms exhibit lower affinity to acrylic resin than to polyamide. (7) Although the surface of polyamide can be easily changed with mechanical factors, polishing the surface is more difficult than the surface of acrylic resin and requires a special polishing procedure.(24) Additionally, repair and reline procedures of polyamide material are difficult because the bonding capacity of polyamides is poor.(14) Because the chemcial etchant and primers can not react with crystalline structure of polyamides. (25) The effect of all these pros and cons on the prognosis of dentures should be considered when planning a polyamide denture.

Although the manufacturers suggest that polyamide dentures are suitable for every cases, there are suggested indications and contraindications due to the properties of the material in previous studies. (5,6,13,20,26) (Table 2 and Table 3).

Table 2. Endications of Polyamide Dentures Without A Metal Structure.

Indications (without a metal structure)
✓ as an interim denture,
✓ dentures for patients suffering from metal allergy,
✓ dentures for replacement of few missing anterior teeth,
✓ when functional forces do not come to dentures as epitheses for patients,
✓ patients with high esthetic expectations,
✓ patients who demand denture without remaining teeth preparation.

Table 3. Contraindications of Polyamide Dentures Without A Metal Structure.

Contraindication (without a metal structure)
× tooth-tissue-supported dentures, when rigid framework is required to protect the support tooth
× when the structural components of the dentures need to be rigid against wear and fracture
× when it is thought that repairing or relining of denture may be needed.
× patients with inadequate oral hygiene,
× Kennedy Class I and Class II cases

Occlusion is another important clinical factor for polyamide dentures. Especially, clinical prognoses of polyamide dentures in patients have few natural teeth and patients without vertical stop occlusion are uncertain. Changes in occlusal contacts and movements of the denture can cause the concentration of occlusal forces and resin components of polyamide dentures may easily be deformed or broken due to the concentration of occlusal forces. (20)

Metal framework can be used to improve strength of polyamide dentures which planned for partially edentulous patients. (10,27) The aesthetic appearance of polyamide dentures and rigidity of metal major connector can be functioned together. Moreover, the metallic occlusal rests of this design controls denture movements under functional forces. (28) It is primarily recommended to use polyamide dentures without metal framework in Kennedy's class III cases, during healing process after oral surgical interventions, and in those who are allergic to acrylic resin and/or metal framework.(27)

With the increasing demands in aesthetic and natural prostheses, interest in polyamide materials is also increasing.

However, clinicians' experiences, manufacturer's recommendations and in vitro studies seem to be the main sources of information about polyamide dentures. Because there are not enough clinical studies to enable us to understand the success of polyamide prostheses. Therefore, polyamide dentures should be carefully planned because their long-term clinical success has not been completely proven.

References

1. Douglass CW, Watson AJ. Future needs for fixed and removable partial dentures in the United States. J Prosthet Dent. 2002;87(1):9-14.

2. Takaichi A, Fueki K, Murakami N, Ueno T, Inamochi Y, Wada J, Arai Y, Wakabayashi N. A systematic review of digital removable partial dentures. Part II: CAD/CAM framework, artificial teeth, and denture base. J Prosthodont Res. 2022;66(1):53-67.

3. Campbell SD, Cooper L, Craddock H, Hyde TP, Nattress B, Pavitt SH, Seymour DW. Removable partial dentures: The clinical need for innovation. J Prosthet Dent. 2017;118(3):273-280.

4. Kim JJ. Revisiting the Removable Partial Denture. Dent Clin North Am. 2019;63(2):263-278.

5. Carr AB, Brown DT: McCracken's removable partial prosthodontics. 12th ed. St Louis: Mosby, 2004.p:8-9.

6. Gözneli R, Akatay ZL, Özkan YK. Esneyebilir hareketli bölümlü protezler. TDD.2012;85:119-123.

7. Bogucki ZA, Kownacka M. Elastic dental prostheses - alternative solutions for patients using acrylic prostheses: Literature review. Adv Clin Exp Med. 2018;27(10):1441-1445.

8. Dąbrowa T, Pławski, A. (2011). Possibilities of prosthodontic treatment with removable partial dentures and telescopic double crowns system. Dent Med Probl.2011;48(1):97-102.

9. Negrutiu M.Thermoplastic resins for flexible framework removable partial dentures. Timisoara Med J. 2005;55:295-299.

10. Fueki K, Ohkubo C, Yatabe M, Arakawa I, Arita M, Ino S, Kanamori T, Kawai Y, Kawara M, Komiyama O, Suzuki T, Nagata K, Hosoki M, Masumi S, Yamauchi M, Aita H, Ono T, Kondo H, Tamaki K, Matsuka Y, Tsukasaki H, Fujisawa M, Baba K, Koyano K, Yatani H. Clinical application of removable partial dentures using thermoplastic resin. Part II: Material properties and clinical features of non-metal clasp dentures. J Prosthodont Res. 2014;58(2):71-84.

11. Takahashi Y, Hamanaka I, Shimizu H. Effect of thermal shock on mechanical properties of injection-molded thermoplastic denture base resins. Acta Odontol Scand. 2012;70(4):297-302.

12 Hishimoto M, Katou Y, Akita Y, Murakami Y, Iida S. (2008). Physical properties of polyester copolymer for denture materials. J Nippon Acad Dent Technol. 2008;29:196.

13. Ito M, Wee AG, Miyamoto T, Kawai Y. The combination of a nylon and traditional partial removable dental prosthesis for improved esthetics: a clinical report. J Prosthet Dent. 2013;109(1):5-8.

14. Takahashi H. Basic properties of thermoplastic resin for denture base materials referred to" non clasp denture". JJ Dent Mater 2009;28:161-167.

15. Takabayashi Y. Characteristics of denture thermoplastic resins for non-metal clasp dentures. Dent Mater J. 2010;29(4):353-361.

16. Sepúlveda-Navarro WF, Arana-Correa BE, Borges CP, Jorge JH, Urban VM, Campanha NH. Color stability of resins and nylon as denture base material in beverages. J Prosthodont. 2011;20(8):632-638.

17. Ebrahimi Saravi M, Vojdani M, Bahrani F. Evaluation of cellular toxicity of three denture base acrylic resins. J Dent (Tehran). 2012;9(4):180-188.

18. Ucar Y, Akova T, Aysan I. Mechanical properties of polyamide versus different PMMA denture base materials. J Prosthodont. 2012;21(3):173-176.

19. Consani RL, Azevedo DD, Mesquita MF, Mendes WB, Saquy PC. Effect of repeated disinfections by microwave energy on the physical and mechanical properties of denture base acrylic resins. Braz Dent J. 2009;20(2):132-137.

20. Fueki K, Ohkubo C, Yatabe M, Arakawa I, Arita M, Ino S, Kanamori T, Kawai Y, Kawara M, Komiyama O, Suzuki T, Nagata K, Hosoki M,Masumi S, Yamauchi M, Aita H, Ono T, Kondo H, Tamaki K, Matsuka Y, Tsukasaki H, Fujisawa M, Baba K, Koyano K, Yatani H. Clinical application of removable partial dentures using thermoplastic resin-part I: definition and indication of non-metal clasp dentures. J Prosthodont Res. 2014;58(1):3-10.

21. Murthy V, Yuvraj V, Nair PP, Thomas S. Prosthodontic management of radiation induced xerostomic patient using flexible dentures. BMJ Case Rep. 2012;20:1-4.

22. Kawara M, Iwata Y, Iwasaki M, Komoda Y, Iida T, Asano T, Komiyama O. Scratch test of thermoplastic denture base resins for non-metal clasp dentures. J Prosthodont Res. 2014;58(1):35-40.

23. de Freitas Fernandes FS, Pereira-Cenci T, da Silva WJ, Filho AP, Straioto FG, Del Bel Cury AA. Efficacy of denture cleansers on Candida spp. biofilm formed on polyamide and polymethyl methacrylate resins. J Prosthet Dent. 2011;105(1):51-58.

24. Abuzar MA, Bellur S, Duong N, Kim BB, Lu P, Palfreyman N, Surendran D, Tran VT. Evaluating surface roughness of a polyamide denture base material in comparison with poly (methyl methacrylate). J Oral Sci. 2010;(4):577-581.

25. Vojdani M, Giti R. Polyamide as a Denture Base Material: A Literature Review. J Dent (Shiraz). 2015;16(1):1-9.

26. Zoidis P, Papathanasiou I, Polyzois G. The Use of a Modified Poly-Ether-Ether-Ketone (PEEK) as an Alternative Framework Material for Removable Dental Prostheses. A Clinical Report. J Prosthodont. 2016;25(7):580-584.

27. Mendoza-Carrasco I, Hotta J, Sugio CYC, Procópio ALF, Urban VM, Mosquim V, Neppelenbroek KH. Nonmetal clasp dentures: What is the evidence about their use? J Ind Prosthodont. 2020;20(3):278.

28.Kutsch VK, Whitehouse JW, Schermerhorn K, Bowers, R. (2003). The evolution and advancement of dental thermoplastics. Dental Town. 2003; 4(2):52-56.

CHAPTER III

ESTHETIC REMOVABLE DENTURES PART II: PRECISION ATTACHMENTS

Kubra Degirmenci
(Assoc.Prof.Dr.) Bolu Abant Izzet Baysal University, Faculty of Dentistry, Department of Prosthodontics, Bolu, Turkey
e-mail:dtkubradegirmenci@outlook.com
ORCID:0000-0001-6429-4923

1. Introduction

Prosthetic treatment planning for partial edentulism is an important topic in dentistry field. There are various treatment options that clinicians can apply in partial edentulism. Implant supported fixed partial dentures or removable partial dentures are treatment options for patients with few natural teeth.

While planning a prosthetic treatment, clinicians concider various factors such as patients' general health condition, patients' demands, and the prognosis of remaining natural teeth. Therefore, in cases where oral surgical procedures cannot be performed, removable partial dentures should be applied instead of implant treatments.(1,2) For instance, removable partial dentures can be preferred instead of implant supported fixed dentures if patients who have severe resorbed alveolar ridges or have defect in the maxillofacial region.(3)

However, metal clasp components are used to provide retention in traditional removable partial dentures and patients can not be satisfied with unnatural gray color of metal clasps. Therefore,

recently, with the increase in aesthetic expectations, precision attachments have become popular. Since precision attachments can hide the metal-colored appearance, aesthetic and natural appearance can be obtained for patients with removable partial dentures.

Precision attachments are systems consisting of matrix (negative, female part) and patrix (positive, male part) components. (1)(Figure 1) Matrix and patrix parts form a good connection with each other and they can be seperated if necessary. This connection type is more esthetic than clasps of traditional removable partial dentures. Further, precision attachments can also be used to solve parallelism problems because of different entrance pathways between abutments. Precision attachments are useful prosthetic connection systems that can be used both as retaining parts in removable dentures and as connecting parts in fixed partial dentures. (4) Moreover, it has been informed that the use of precision attachments in removable partial dentures has a positive effect on quality of life of partially edentulous patients.(5)

Figure 1. Schematic view of components of precision attachments

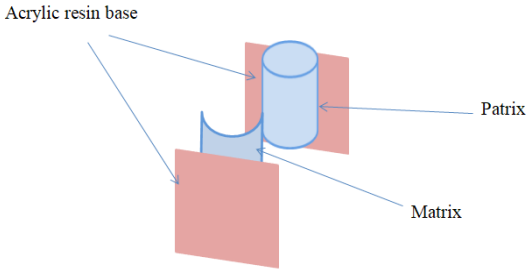

2. Classifications of Precision Attachments

Precision attachments are the connection between the matrix part on the abutment tooth and patrix part placed on it and these attachments can also be used in implants or maxillofacial obturators.

(6,7) However, precision attachments are more commonly used to connect a fixed denture with a removable partial denture.

When an esthetic removable partial denture with precision attachment is planned, clinician has to choose proper attachment type from a wide variety of precision attachment types. There are various type of attachments and the retention features of attachments vary based on their type, design, and wear characteristic (8) vertical dimension, force distribution on occlusal surfaces and oral tissues, and level of expected retention of denture are important factors while deciding type of attachments.(9,10) Abutment teeth with poor bone support, low vertical dimension, poor oral hygiene have been reported as risk factors that may adversely impact the success of precision attachment dentures.(11,12) When precision attachment type is not properly selected, fracture of the abutment teeth, poor retention of the dentures, and even breakage of the major connector may be seen.(13) Therefore, a new prosthetic treatment may be required. Actually, precision attachments do not have any advantage over each other, but attachment type should be properly selected according to the case.

There are different classifications for precision attachments according to their fabrication methods , shape ,and designs. Precision attachments can be classified as precision attachments and semi-precision attachments according to their fabrication method and the tolerance degrees of fit between components.(14,15) (Figure 2.)

Figure 2. Schematic view of type of precision attachments based on their fabrication and tolerance characteristics.

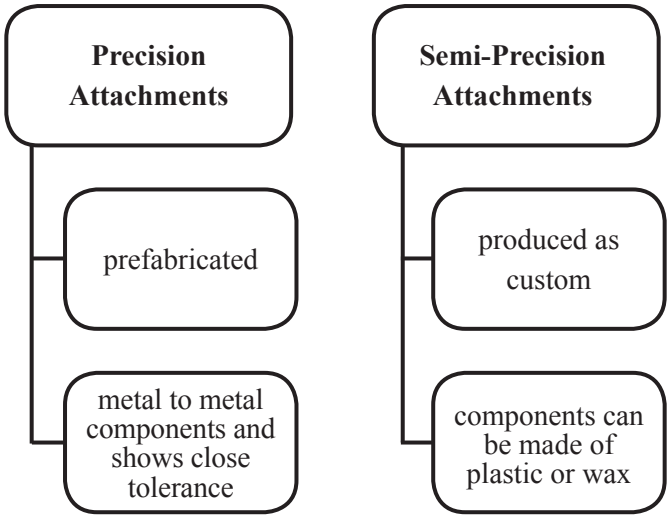

There is another classification according to shape, design ,and utilization region of precision attachments. (16,17) (Figure 3).

Figure 3. Schematic view of shape of precision attachments based on their design and utilization region characteristics.

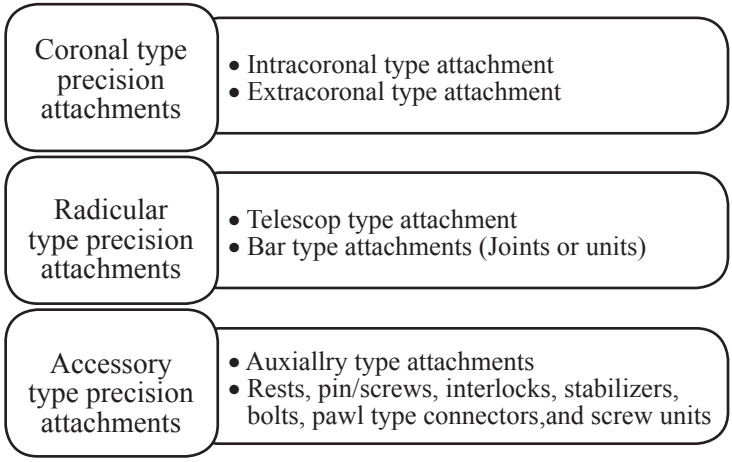

2.1. Intracoronal Precision Attachments

In order to apply intracoronal precision attachment system, the male part must be placed inside the removable partial denture and the female part must be placed within the crown boundaries of the abutment tooth.(15) Therefore, tooth preparation is needed. Rigid connection can be achieved with this attachment type. There are some suggested indications and contraindications for intracoronal precision attachments.(18,19)

Indications:

✓ Kennedy Class III and Kennedy Class IV cases.

✓ Vertical dimensions of abutment teeth are adequate to be retentive after preparation.

✓ In cases where the abutment teeth are not parallel to partial dentures.

✓ In cases with complete dentures or Kennedy Class I removable dentures in the opposite dental arch.

✓ They can be planned in teeth supported removable dentures because they do not allow rotation of the denture base.

Contraindications:

× Kennedy Class I and Kennedy Class II cases because of different resiliens.

× The mesial part of anterior teeth because of non esthetic appearance.

× In cases where the clinical crown length of abutment teeth are short and pulp chambers are wide.

2.2. Extracoronal Precision Attachments

The male and female parts of extracoronal precision attachments are located on outside contour of crown and these type attachments

can be rigid or resilient.(15) It is recommended to include at least two abutment teeth in the planning, as negative torque forces may occur on the abutment teeth due to their extracoronal position. (20) Indications and contraindications for extracoronal precision attachments are reported in previous researches. (15,21,22)

Indications:

✓ In cases which the crown lengths of abutment teeth are inadequate.

✓ Kennedy Class I and Kennedy Class II cases due to their stress breaker nature.

✓ In cases which metal clasps are contraindicated due to high esthetic demands.

✓ In removable partial dentures with distal extension because they can improve stability and retention of dentures.

Contraindications:

× Patients with poor oral hygiene

× Periodontal problems

× Patients with bruxism.

Besides, there is a detailed classification of rigid and resilient precision attachments based on their functions (Table 1) and it is suggested that rigid attachments can be used for abutment-tooth retained dentures, and resilient attachments can be preferred for abutment-tooth and tissue retained dentures.(22)

Table 1. The detailed classifications of rigid and resilient precision attachments.

Classification	Subgroups	Precision Attachment Examples
Solid type precision attachments	Class 1a: (there is no movement between the tooth and the attachments)	Intracoronal: *Score-BR, Score-PD, Beyeler,PDC, Omega-M, Interlock* Extracoronal: *SwissEx, D2.7 and D3.0, OT strategy, Vario*
	Class 1b: (it is similar to class 1a but female and male parts are connected by a screw or U-pin)	*SCORE-UP,Swiss-Bloc,Screw-Bloc, MK1,SwissLog NG, Dalbo, ASC 52, Swiss Mini, Ceka*
Resilient type precision attachments	Class 2: Vertical resilient type (attachments allow movements in only vertical plane)	*TSE, Vertica*
	Class 3: Hinge resilient type (attachments allow movements around only a specific point)	*Dalbo minor, Swiss Minor, Ancorvis Gilmar,SwissMar, May's Ackermann System, SwissAnchor OD,*
	Class 4: Vertical and Hinge resilient type (it allows simultaneous movement in the vertical plane and the hinge axis	*DalboS, Ultra-M, Locator Direct*
	Class 5: Rotational and vertical resilient type (it can allow vertical resilient during rotational movement)	*SwissAnchor SA, ERA, ASC 52, ZAAG, Locator Bar retained, Allegro OD, Uni-Anchor*
	Class 6: Universal, omni-planar resilient type (it allows movement in multi planes)	*ORS, Logic, ORS-DE,O-Ring System,Zaag*

2.3. Telescopicic type attchments

Telescopic type attachments are good at solving entry pathway problems. Restorations prepared with telescopic type attachments can be applied in various indications, from fixed partial dentures to overdentures. (23) Vertical and bucco-lingual distance of dental arches should be sufficient. Telescopic type attachments can be preferred in the presence of a few abutment teeth and in cases where the clinical crown lengths of the abutment teeth are short. (24) Telescopic type attachments can direct occlusal forces to alveolar bone along the long axis of abutment teeth and they can keep stable.(25) However, it is recommended that telescopic type attachments should be used in patients with good oral hygiene, because the attachments may exert pressure on interdental papilla. (26) Telescopic type attachments may provide long-term success when they are used for appropriate cases.(11,27)

2.4. Bar type Attachments (Joints of Units)

Bar type attachments can be in various shapes, including round or angular.(28,29) Round-sectioned attachments can be locked with clips, while angular-sectioned atachments can provide retention with frictional forces.(23) Bar type attachments can be used as a component that connects implants, teeth and/or roots.(11,28,29) Therefore, bar type attachments can equally distribute occlusal forces and they can also be used to increase retention of complete dentures. They can also be used on teeth with poor periodontal health, as they have a splinting effect.(22) However, bar type attachments are not suggested for use in patients with inadequate distance between dental arches and in patients with poor oral hygiene.(30)

3. Conclusion

Removable partial dentures with precision attachments are good treatment options to meet aesthetic expectations of patients, especially

when fixed dentures cannot be planned. Further, lateral forces due to clasps of traditional removable partial dentures are prevented by precision attachments. However, clinicians should have sufficient knowledge and experience about precision attachment types and they should evaluate all risks of treatment by performing a detailed clinical examination at the beginning of prosthetic treatment. Precision attachment type to be chosen without proper planning may jeopardize patient's remaining support tissues, natural teeth, and the success of denture. Therefore, if removable partial dentures with precision attachments are prepared after correct planning, they will be successful and will improve patients' oral quality of life.

References

1. Hedzelek W, Rzatowski S, Czarnecka B. Evaluation of the retentive characteristics of semi-precision extracoronal attachments. J Oral Rehabil. 2011;38(6):462-468.

2. Wang HY, Zhang YM, Yao D, Chen JH. Effects of rigid and nonrigid extracoronal attachments on supporting tissues in extension base partial removable dental prostheses: a nonlinear finite element study. J Prosthet Dent. 2011; 105(5): 338-346.

3. Kesim B. Haraketli Bölümlü Protezlerde Temel İlkeler, 1. Baskı Türkiye: Quintessence Publishing; 2010 p.171-173.

4. Nguyen CT, Masri R, Driscoll CF, Romberg E. The effect of denture cleansing solutions on the retention of pink Locator attachments: an in vitro study. J Prosthodont. 2010;19(3):226-230.

5. Bayer S, Keilig L, Kraus D, Grüner M, Stark H, Mues S, Enkling N. Influence of the lubricant and the alloy on the wear behaviour of attachments. Gerodontology. 2011;28(3):221-226.

6. The Glossary of Prosthodontic Terms: Ninth Edition. J Prosthet Dent. 2017;117(5):1-105.

7. Shetty PP, Chowdhary R, Shetty PP. A maxillofacial prosthetic obturator using precision attachments. Indian J Dent Res. 2020;31(5):799-802.

8. Deste Gokay G, Ozkir SE, Wolf TG, Gokcimen G, Rona N, Bicer M, Yilmaz B. The effect of denture cleansing solutions on the retention of precision attachments: An ın vitro study. Int J Environ Res Public Health. 2022;19(7):4345.

9. Munot VK, Nayakar RP, Patil R. Prosthetic rehabilitation of mandibular defects with fixed-removable partial denture prosthesis using precision attachment: A twin case report. Contemp Clin Dent. 2017;8(3):473-478.

10. Jeyavalan MI, Narasimman M, Venkatakrishnan CJ, Philip JM. Management of long span partially edentulous maxilla with fixed removable denture prosthesis. Contemp Clin Dent. 2012;3(3):314-316.

11. Ekren O, Kurtoğlu C. Hassas bağlantılar. Atatürk Üniv Diş Hek Fak Derg. 2008;18(1):111-120.

12. Baran İ, Bulut AC. Geriatrik hastalarda protetik tedavi alternatifleri. Türk Geriatri Derg. 2010;13(1): 67-72.

13. Tokar E, Uludağ B, Karacaer Ö. Çift taraflı serbest sonlu dişsizlikte yeni bir hassas tutucu uygulaması: bir olgu bildirimi. Acta Odontol Turc. 2013;30(3):145-148.

14. Jain R, Aggarwal S. Precision attachments-An overview. IP Ann Prosthodont Restor Dent. 2017;3(1):6-9.

15. Kanathila H, Doddamani MH, Pangi A. (2018). An insight into various attachments used in prosthodontics: A review. Int J Appl Dent Sci. 2018;4(4):157-160.

16. Mensor MC. Classification and selection of attachments. J Prosthet Dent. 1973;29(5):494-497.

17. Preiskel HW, Preiskel A. Precision attachments for the 21st century. Dental Update. 2009;36;(4):221-227.

18. Holst S, Blatz MB, Eitner S, Wichmann M. In vitro wear of different material combinations of intracoronal precision attachments. Int J Prosthodont. 2006;19(4):330-332.

19. Saito M, Miura Y, Notani K, Kawasaki T. Stress distribution of abutments and base displacement with precision attachment-

and telescopicic crown-retained removable partial dentures. J Oral Rehabil. 2003;30(5):482-487.

20. Altay OT, Tsolka P, Preiskel HW. Abutment teeth with extracoronal attachments: the effects of splinting on tooth movement. Int J Prosthodont. 1990;3(5):441-448.

21. Li J, Wang H, Liu Z. The stress model of abutment tooth and periodontal tissues with unilateral mandibular dissociation and loss by precision extracoronal attachment. Saudi J Biol Sci. 2019;26(8):2118-2121.

22. Uludağ B, 2012. Hassas tutucular implant vakalarında sorunlar ve çözümler, Baskı 1. Türkiye, ADA, p. 20-22.

23. Minagi S, Natsuaki N, Nishigawa G, Sato T. New telescopicic crown design for removable partial dentures. J Prosthet Dent. 1999;81(6):684-688.

24.Hinz S, Schweyen R, Hey J, Setz J, Arnold C. Clinical performance of non-precious metal double crowns with friction pins in severely reduced dentitions. Clin Oral Investig. 2020;24(10):3567-3575.

25. Burns DR, Ward JE. Review of attachments for removable partial denture design: 1. Classification and selection. Int J Prosthodont. 1990;3(1):98-102.

26. Etienne OM, Taddei CA. Use of bar-clip attachments to enhance the retention of a maxillofacial prosthetic obturator: a clinical report. J Oral Rehabil. 2004;31(6):618-621.

27. Wöstmann B, Balkenhol M, Weber A, Ferger P, Rehmann P. Long-term analysis of telescopicic crown retained removable partial dentures: survival and need for maintenance. J Dent. 2007;35(12) :939-945.

28. Nassar HI, Abdelaziz MS. Retention of bar clip attachment for mandibular implant overdenture. BMC Oral Health. 2022;22(1):227.

29. Deniz A, Özkan Y. Hassas bağlantılı protezler ve uygulamasında dikkat edilmesi gereken kriterler. Atatürk Üniv. Diş Hek. Fak. Derg. 2012;6: 132-141.

30. Chung KH, Chung CY, Cagna DR, Cronin RJ Jr. Retention characteristics of attachment systems for implant overdentures. J Prosthodont. 2004;13(4):221-226.

CHAPTER IV

PERIODONTAL DISEASES IN CHILDREN

Kübra Mumcu[1] & Yusuf Yüncü[2] & Mehmet Sinan Doğan[3]

[1]Harran Üniversitesi, Diş Hekimliği Fakültesi, Şanlıurfa/ TURKİYE. dt.kubramumcu@harran.edu.tr
ORCID ID: 0000-0002-2597-312X

[2]Harran Üniversitesi, Diş Hekimliği Fakültesi, Şanlıurfa/ TURKİYE. yzyuncu@harran.edu.tr
ORCID ID: 0000-0002-4417-4526

[3]Harran Üniversitesi, Diş Hekimliği Fakültesi, Şanlıurfa/ TURKİYE. drmsdogan@harran.edu.tr
ORCID: 0000-0002-3089-1305

1. Introductıon

Gingival and periodontal diseases in children are rarely encountered. However, the prevalence and severity of periodontal diseases increase from childhood to adulthood. There seems to be a relationship between the age-dependent development of periodontal diseases and the characteristics of oral tissues.[1]

1.1. Differences between periodontal structures in children and adults;

Keratinization of the gingiva in children is less. For this reason, the presence of the underlying vascularized tissue causes a color change that can be confused with inflammation. During the transition from

the primary dentition to the permanent dentition, significant changes occur in the periodontal structures. Most changes are associated with the eruption and this is physiological.[2] During the period when the teeth are erupting, the redness of the gums is local and sometimes permanent. The interdental gingiva spreads over a wider area in the fascio-lingual direction. The gingival margin is thick and roll-shaped, with a softer consistency. In addition, stipling appears on the gums around the age of 3 years. Stipling is seen in 56% of children aged 3-10 years.[3,4]

Alveolar bone spaces are less calcified, wider, lymphatic drainage and blood supply are more. There is also a thinner lamina dura in the alveolar bone and less trabeculation. The interdental septum runs straight, 1-2 mm apical to the cementum-enamel boundary. In children, the periodontal membrane is thicker and the fiber bundle density is less. In addition, the periodontal membrane is rich in blood vessels and contains water. Cemented tissue, on the other hand, may be less calcified and hyperplasic. Due to these differences, the development of periodontal disease increases during the primary dentition.[2,3,4]

Hormonal changes in children can also cause changes in periodontal structures. Estrogen and progesterone levels increase with the pubertal development of the child in the permanent dentition period. However, dilatation is observed in the capillary blood vessels in the gums. With the increase in dilatation, edema, hyperplasia and gingival bleeding can be seen in the gums. With the increase in vascular permeability, leukocyte migration to the inflamed tissue may occur, resulting in granulation tissue formation and endothelial destruction.[5] Since the junctional epithelium in the attached gingiva is thicker in the primary dentition compared to the permanent dentition, its permeability is lower. As a result, the possibility of infiltration of bacterial toxins into the gingival tissues and initiation of inflammation in the primary dentition period decreases.[2]

1.2. Etiology of periodontal diseases in children

The main etiological factor of periodontal diseases is microbial plaque, which can cause destruction of gingival tissues and periodontal attachment.[6] The normal ecology of the mouth contains a large number of bacteria. Many of these are virulence. Microorganisms that play a role in the pathogenesis of gingivitis are any important non-specific substances that accumulate in certain areas. The amount of bacteria and bacterial products is the most important factor in gingivitis.[7] Periodontal inflammation, on the other hand, develops with an increase in the number of gram-negative bacteria and anaerobes in the subgingival plaque.[8] Microorganisms that are frequently associated with periodontal diseases; Aggregatibacter (Actinobacillus), Tanerella forsythensis, Porphyromonas gingivalis and Treponema denticola.[9]

Local factors such as flooded fillings or fractured-edged restorations, significant caries lesions, dental malpositions, malocclusions, orthodontic appliances, proximal and palatogingival grooves may also cause microbial plaque accumulation and thus periodontal disease development.[10] For all these reasons, oral hygiene should be provided in children immediately after teeth eruption and regular brushing habits should be introduced.[11]

Gingival inflammation may occur in children with mouth breathing or inadequate lip closure. Mouth breathing causes drying of the gums in the anterior regions. These lead to vascular contraction and decrease in host resistance.[12] Apart from these, traumatic, developmental, genetic, neoplastic and metabolic factors, some drugs (nifedipine, cyclosporine A, phenytoin, dilantin) and some systemic diseases (diabetes mellitus, leukemia, agranulocytosis) can cause gingival and periodontal diseases.[7,13]

Periodontal diseases that occur in adulthood can be seen as a continuation of milder gingival diseases in childhood. The most common gingival diseases in childhood are plaque-related gingivitis and gingivitis associated with puberty.[14] Many forms of periodontal

disease can occur in children and adolescents. Diseases such as plaque-induced gingivitis, non-plaque gingival diseases (herpetic gingivostomatitis, candida), chronic periodontitis, aggressive periodontitis, necrotizing periodontal diseases, periodontitis associated with endodontic lesions, periodontal abscess, developmental and acquired deformities and conditions constitute the forms of periodontal disease.[15]

1.3. Pubertal gingivitis

With the onset of the pubertal period, changes in gonadotropic hormone levels and normal and abnormal fluctuations in hormone levels can change the gingival inflammation response resulting from microbial plaque. During this period, significant inflammation, bluish-red discoloration, hyperplasia and edema in the gingiva can generally be local factors that will cause a mild gingival response.[16] The most common manifestation of pubertal gingivitis is inflammatory gingival enlargement with interproximal gingival hemorrhage, which usually resolves in adulthood.[17]

While the primary etiological factors are microbial plaque and calculus in pubertal gingivitis, hormonal changes are secondary or modifying factors.[16] It is known that hormonal changes that occur during puberty increase the risk of periodontitis.[18] Therefore, it is very important to eliminate primary and secondary factors in the treatment of pubertal gingivitis.[19]

1.4. Eruption gingivitis

It is a term used to describe very intense inflammatory reactions around erupted teeth and in the gums during eruption of permanent teeth. The gingiva around the erupted tooth may appear reddish in color. This is because the keratinization of the gingival margin and the development of the sulcus have not yet been completed. The causative agent of eruptive gingivitis is the exfoliation of primary

teeth and eruption of permanent teeth, causing inflammatory reactions as tooth brushing is difficult or undesirable, causing excessive plaque accumulation.[7]

1.5. Plaque-induced gingivitis

Plaque-induced gingivitis is the most common type of periodontal disease in childhood, and microbial plaque is its primary cause.[20] Plaque-induced gingivitis affects 70% of children older than 7 years of age.[19] Reversible gingival inflammation occurs in the gingival margin as a result of plaque accumulation. Inflammation is mostly confined to the marginal gingiva and does not usually develop into periodontitis. Because there are differences in the host response during inflammation.[21] In children, the number of B lymphocytes and plasma cells is less than the number of T lymphocytes. At the same time, plasma cells that increase in advanced periodontal diseases are relatively less. All these are seen as the reason why gingivitis is painless and does not involve deep periodontal tissues.[2,4,7] However, sometimes bone and connective tissue attachment losses occur and gingivitis can turn into periodontitis in later ages.[19] The main types of bacteria that cause the inflammatory response in the gingiva and are also included in the plaque; Actinomyces, Streptococcus, Prevotella, Eubacterium, Capnocytophaga and Fusobacterium.[22]

The clinical manifestations of plaque-induced gingivitis are gingival hyperplasia, edema and bleeding.[23] The treatment of plaque-incuded gingivitis is to provide oral hygiene and plaque control. Acquiring the habit of brushing the teeth can be done by ensuring the interface cleaning. In cases where gingivitis is very severe, professional scaling should be done to remove plaque and calculus under the gums.[7]

1.6. Non-plaque gingivitis

Although the incidence of non-plaque gingivitis is less than that of plaque-induced gingivitis, it is often of great importance for patients.

Non-plaque gingival inflammations are often manifestations of systemic disorders or conditions. However, it can also show pathological conditions limited to gingival tissues. In the etiology of inflammation, there are genetic/developmental disorders, some specific infections of viral, bacterial or candidal origin, neoplasms, vitamin deficiencies, traumatic lesions and immune conditions/ lesions.[15]

1.7. Primary herpetic gingivostomatitis

Primary herpetic gingivostomatitis is an acute and contagious disease caused by the herpes simplex virus Type 1 (HSV-1). It is usually seen in infants and children younger than 6 years of age, but can also be seen in adolescents and adults. The primary infection of the disease is frequently asymptomatic.[24] Clinically, the oral mucosa and gingiva appear with varying degrees of edema, bleeding and diffuse, erythematous bright involvement. At the initial stage, gray vesicles of different sizes are seen on the gingiva, tongue, pharynx, sublingual mucosa, soft palate, cheek and lip. These vesicles rupture after approximately 1 day. These turn into painful small ulcers. The edges of these ulcers are red, the middle part is in the form of a yellowish halo or gray-white areas. These symptoms can be seen as separate large areas or as merged clusters. Acute herpetic gingivostomatitis, on the other hand, occurs after primary infection. Oral infection is also seen with systemic symptoms. Acute herpetic gingivostomatitis continues for 1 week-10 days and heals without scarring.[25] The treatment is to relieve the patient by eliminating the symptoms and to prevent secondary infections or systemic disorders that may occur. Bed rest, soft diet and adequate hydration and paracetamol suspension are recommended to the patient. With the use of chlorhexidine, secondary infection of ulcers is prevented. As systemic treatment, antivirals (acyclovir), analgesics (acetaminophen) and topical anesthetics are given.[26]

1.8. Acute necrotizing gingivitis (ANUG)

It is a disease characterized by painful and hemorrhagic oral papillary ulceration and pseudomembranous necrotic exudate formation along the gingival margin.[27] In addition, its clinical features are usually accompanied by halitosis.[24] It is more common in children in underdeveloped countries with malnutrition problems. It is an important cause of morbidity in children whose immune system is suppressed and malnourished.[27]

Microorganisms such as Treponema, Fusobacterium, Selenomonas species and Prevotella intermedia are frequently encountered in necrotizing gingivitis. Its treatment is rinsing the mouth with 0.1% chlorhexidine or 0.5% hydrogen peroxide (H_2O_2) in children. In addition, professional plaque removal is required. Antibiotics are given in cases where the patient does not respond to the cleaning of infected tissues after surgery, where there is a risk of spreading the infection or when it threatens general health.[7]

1.9. Chronic periodontitis

The occurrence of periodontitis is extremely rare in children and adolescence and increases with age.[28] Periodontitis; It turns into a thin and ulcerated pocket epithelium with the apical migration of the junctional epithelium, which is close to the border in the cervical region of the tooth. In addition, it is a periodontal disease with loss of periodontal attachment and loss of alveolar bone. From time to time, devastating and rapid attacks can be seen in chronic periodontitis. It is also a form of periodontitis with a low to medium progression rate.[13]

The classification of chronic periodontitis can be made according to its prevalence and severity. According to the affected area, the disease is called localized and generalized. If the affected area is less than or equal to 30%, it is defined as ‘localized’, and if it is more than this rate, it is defined as ‘generalized’. In addition,

classification is made according to clinical attachment loss. Attachment loss is classified as 'mild' if it is 1-2 mm, 'moderate' if 3-4 mm, and 'severe' if it is equal to or greater than 5 mm.[29]

Loss of periodontal support in young children is usually seen as single lesions in primary molars. Pocket depth is limited in affected primary teeth. It is characterized by accidental loss of attachment in the teeth in this region, mostly associated with various types of local traumas or due to various factors related to the development of dentition. This type of disorder may also show a period that has previously had an inflammatory process but has recovered. But more importantly, it can also indicate an initial stage of progressive periodontal disease.[7]

Aggressive Periodontitis is also known as juvenile periodontitis. It is thought to be common in pubertal children and adolescents. There is rapid loss of alveolar bone and connective tissue attachment with familial aggregation. Aggressive periodontitis is caused by abnormalities in host defense mechanisms together with pathogenic microflora.[3] Aggregatibacter actinomycetemcomitans, Porphyromonas gingivalis are frequently seen in the microbial biofilm of aggressive periodontitis, as in chronic periodontitis.[30]

Generalized aggressive periodontitis; It is characterized by a generalized loss of interproximal attachment affecting at least three more permanent teeth other than the incisors-permanent first molar, usually seen in those younger than the middle age group (30 ≤), and a weak serum antibody response to the infecting agent. If localized aggressive periodontitis; It is characterized by onset in adolescence, loss of interproximal attachment in at least two of the incisors, the permanent first molar and at most two of the other teeth, and the ability to form strong serum antibodies, particularly against Aggregatibacter actinomycetemcomitans.[13]

The success of the treatment of localized aggressive periodontitis depends on early diagnosis, direct elimination of pathogenic microorganisms and providing a healthy environment

free from infection. Surgical/non-surgical root debridement with the use of antibiotics is the most appropriate treatment. The most successful antibiotic reported is tetracycline and can sometimes be prescribed in combination with metronidazole.[31] While the use of antibiotics together with surgical or non-surgical root debridement is very effective in the treatment of localized aggressive periodontitis, it has been reported that generalized patients do not respond very well to this treatment or antibiotics. Alternative antibiotics should be selected according to the pathogenic flora in patients with generalized aggressive periodontitis that do not respond to standard periodontal therapy.[12]

Children and adolescents are exposed to various periodontal diseases. Therefore, during routine dental examination, evaluation should be made in terms of periodontal conditions and diseases. During this examination, the signs of growth and development on periodontal tissues in children and adolescents should be well known and the mechanism and causes of the types of periodontal diseases that may occur according to age groups should be understood. Even if periodontal problems are not common in children, it should not be forgotten that every gingivitis has a tendency to turn into periodontitis in the future. For this reason, early diagnosis is important and necessary for successful treatment.

References

1. Tadjoedin FM, Fitri AH, Kuswandani SO, Sulijaya B, Soeroso Y. The correlation between age and periodontal diseases. Journal of International Dental and Medical Research. 2017;10(2):327-332.

2. Newman MG, Takei H, Klokkevold PR,Carranza FA. Newman and Carranza's Clinical periodontology E-book: Elsevier Health Sciences. 2018: 604-6015.

3. Al-Ghutaimel H, Riba H, Al-Kahtani S, Al-Duhaimi S. Common periodontal diseases of children and adolescents. Int J Dent. 2014; 2014:850674.

4. Heasman PA, Waterhouse PJ. Periodontal diseases in children. Paediatric dentistry. 2005 :231-256.

5. Mascarenhas P, Gapski R, Al-Shammari K, Wang HL. Influence of sex hormones on the periodontium. J Clin Periodontol. 2003;30(8):671-81.

6. Pihlstrom BL, Michalowicz BS, Johnson NW. Periodontal diseases. The Lancet. 2005;366(9499):1809-1820.

7. Koch G, Sven P. Pediatric dentistry a clinical approach. Second ed. Rotatif Publisher. 2007:166-181.

8. Ramberg P, Sekino S, Uzel NG, Socransky S,Lindhe J. Bacterial colonization during de novo plaque formation. Journal of Clinical Periodontology. 2003; 30(11): 990-995.

9. Mineoka T, Awano S, Rikimaru T, Kurata H, Yoshida A, Ansai T, Takehara T. Site-specific development of periodontal disease is associated with increased levels of Porphyromonas gingivalis, Treponema denticola, and Tannerella forsythia in subgingival plaque. J Periodontol. 2008 ;79(4):670-676.

10. Cabanilla L, Molinari G. Clinical considerations in the management of inflammatory periodontal diseases in children and adolescents. Journal of Dentistry for Children. 2009;76(2):101-108.

11. Botero JE, Rösing CK, Duque A, Jaramillo A, Contreras A. Periodontal disease in children and adolescents of Latin America. Periodontol 2000.2015;67(1):34-57.

12. Çalışır M, Akpınar A. Çocuklarda ve adolesanlarda periodontal hastalıklar. Cumhuriyet Dental journal. 2013;16(3): 226-234.

13. Durmuşlar S, Akcabaş B. Çocuklarda ve adolesanlarda periodontal hastalıklar ve erişkinliğe etkisi. Journal of International Dental Sciences. 2017;1: 8-16.

14. Gafan GP. A community analysis of dental plaque in pre-pubertal children. University of London, University College London (United Kingdom), 2007:22-80.

15. Holmstrup P, Plemons J, Meyle J. Non-plaque-induced gingival diseases. J Clin Periodontol. 2018; 45(20):28-43.

16. Kinane DF, Peterson M, Stathopoulou PG. Environmental and other modifying factors of the periodontal diseases. Periodontology 2000, 2006;40(1):107-119.

17. Modéer Thomas, Wondimu B. Periodontal diseases in children and adolescents. Dental Clinics of North America. 2000; 44(3): 633-658.

18. Kumar PS. Sex and the subgingival microbiome: do female sex steroids affect periodontal bacteria?. Periodontology 2000.2013;61(1):103-124.

19. Oh TJ, Eber R, Wang HL. Periodontal diseases in the child and adolescent. Journal of clinical Periodontology. 2002; 29(5): 400-410.

20. Kasuma N, Fitri H, Fajrin FN, Ernesto G, Juwita DR, Octaricha T. Effect of zinc supplementation on salivary mmp-8 level in male wistar rats with experimental periodontitis for a better dental care. Journal of International Dental and Medical Research. 2021;14(3):977-981.

21. Özgür B. Çocuk diş hekimliğinde dişeti hastalıkları ile sistemik hastalıkların ilişkisi. Turkiye Klinikleri J Pediatr Dent-special Topics 2016;2(2):8-17.

22. Patil S, Rao RS, Sanketh DS, Amrutha N. Microbial flora in oral diseases. J Contemp Dent Pract. 2013;14(6):1202-1208.

23. Murakami S, Mealey BL, Mariotti A, Chapple ILC. Dental plaque-induced gingival conditions. J Clin Periodontol. 2018; 45:17-27.

24. Pari A, Ilango P, Subbareddy V, Katamreddy V, Parthasarthy H. Gingival diseases in childhood–a review. Journal of Clinical and Diagnostic Research: jcdr. 2014; 8(10): 01-04.

25. Dal A, Dönertaş ŞN. Çocuklarda akut periodontal hastalıkların teşhis ve tedavisi. Turkish Journal of Clinics and Laboratory. 2020; 11(1): 68-74.

26. Verma D, Jhawar A, Khinda N, Anand D. Gingival diseases in childhood: a review. Global journal of medical research. 2014;14(3): 17-22.

27. Miyairi I, Franklin JA, Andreansky M, Knapp KM, Hayden RT. Acute necrotizing ulcerative gingivitis and bacteremia caused by Stenotrophomonas maltophilia in an immunocompromised host. Pediatr Infect Dis J. 2005;24(2):181-183.

28. AlGhamdi A, Almarghlani A, Alyafi R, Ibraheem W, Assaggaf M, Howait M, Alsofi L, Banjar A, Al-Zahrani M, Kayal R. Prevalence of periodontitis in high school children in Saudi Arabia: a national study. Ann Saudi Med. 2020; 40(1):7-14.

29. Armitage GC. Development of a classification system for periodontal diseases and conditions. Northwest Dentistry. 2000;79(6):31-35.

30. Kinane DF, Stathopoulou PG, Papapanou PN. Periodontal diseases. Nature Reviews Disease Primers. 2017; 3(1): 1-14.

31. Mohammad karimi DMD, Dehghan H. Comparison of the efficacy of plaque removal of listerine smart rinse kids and vi–one junior fluoridated mouthwash in children aged 6 to 10 years. 2019;3(1):197-200.

CHAPTER V

DENTAL CONSIDERATIONS ABOUT FAMILIAL MEDITERRANEAN FEVER (FMF) DISEASE

Melek Tassoker[1]

[1]*(Assoc. Prof.), Department of Dentomaxillofacial Radiology, Necmettin Erbakan University, Faculty of Dentistry*

e-mail: dishekmelek@gmail.com

ORCID: 0000-0003-2062-5713

Introduction

FMF, also known as Familial Mediterranean Fever, is an autosomal recessive inherited condition and is the most common autoinflammatory disease in the world. Common symptoms are fever, pleuritis, arthritis, peritonitis, and the most serious complication is amyloidosis (1). It has been determined that serum Amyloid A and C Reactive Protein (CRP) levels increase during the attack periods of the disease. This caused the studies to focus on proinflammatory cytokines, and it was determined that proinflammatory cytokines were high during attacks or between attacks. It is stated that periodontal diseases that manifest with acute phase markers such as high proinflammatory cytokines, CRP and fibrinogen in the body have a higher prevalence in FMF patients (2). In recent years, many studies investigating the relationship between FMF and periodontal diseases have been published (3-6). In some of these studies, it is stated that FMF and periodontal diseases may have similar genetic backgrounds (7-9). The aim of this paper is to

present the dental approach in FMF patients in the light of current literature.

1. Epidemiology and pathogenesis

FMF is most common in Middle Eastern Arab peoples, Sephardic and Iraqi Jews, Armenians, Turks, and North African people. It is also found in countries such as Poland, Greece, Italy, Belgium, Cuba and Australia (10). The frequency of the disease in Turkey is approximately 1/1000 and the carrier rate is 1:5 (4). It is reported that 24% of FMF patients are in Central Anatolia, 70% are in Eastern Anatolia and Black Sea, and a small portion is in the Aegean Region (1).

Regarding FMF, it is stated that the M694V mutation is most common in Turkish population (11). Studies report that the M694V mutation is a severe form of FMF, and patients with homozygous mutations with M694V are at increased risk of developing amyloidosis (1). FMF patients with homozygous M694V mutations appear to show more severe symptoms than patients with heterozygous mutations.

The pathogenesis of FMF resulted from the emergence of the MEFV (MEditerranean FeVer) gene encoding the pyrin protein (12). This gene, called MEFV, has 3505 nucleotides and consists of 10 exons. Mutations in FMF patients usually affect the B30.2 region. Any mutation in the MEFV gene prevents the anti-inflammatory function of the pyrin protein, so disease symptoms occur. Pathogenic variants according to studies M694V, M694I, M680I, V726A, R761H, A744S, I692del, E167D, T267I; variants of uncertain significance I591T, F479L, E148Q, K695R, P369S; normal ones are R408Q, R202Q mutations (13).

2. Clinical features

In most patients, symptoms begin before the age of 10 (14). FMF is characterized by various types of attacks accompanied by fever.

Between attacks, the patient is completely healthy and does not show any other symptoms. The duration of attacks is variable, usually 2-4 days (15). Patients can continue their lives for a long time without experiencing an attack, and sometimes the intervals between attacks are very short. In 90% of patients, attacks begin before the age of 20. The leading factors are stress, climatic conditions and individual intolerances. Common manifestations of FMF are: recurrent fever, abdominal pain, arthritis/arthralgia, pleuritis, pericarditis, and amyloidosis (13).

3. Diagnosis

When making a diagnosis, help is taken from genetic tests. Patients with MEFV gene mutations are accepted if they meet other diagnostic criteria, but as can be seen from the examples, genetic testing is not a clear diagnostic or refusing criterion. Taking into account the low prevalence of mutations that have not yet been identified, genetic testing is only a good help for common mutations. Colchicine treatment is started for 3-6 months in patients who cannot be sure of having FMF, and the diagnosis is made by looking at the course of the attacks. Tel-Hashomer criteria are the leading criteria used for diagnosis in the clinic (15). Accordingly, Major Criteria: (1) Recurrent febrile attacks with peritonitis, synovitis or pleuritis, (2) AA type amyloidosis, (3) Colchicine response, Minor criteria: (1) Recurrent fever attacks, (2) Erysipelas-like erythema, (3) A history of FMF in first-degree relatives. Definitive diagnosis: 2 major or 1 major + 2 minor criteria, Suspicious diagnosis: 1 major +1 minor criteria (16).

4. Treatment

Colchicine has been used in the treatment of FMF attacks since 1972. Colchicine prevents attacks as well as the development of amyloidosis, which is an important complication. In the study

conducted in Israel (17), in cases followed for 11 years; while only 2% of the patients using colchicine developed amyloidosis, it was observed that 49% of the patients who used colchicine irregularly or did not use it at all, developed amyloidosis in cases followed for 9 years. The recommended dose of colchicine is 1–1.5 mg per day, regardless of the severity of the disease, age and weight of the patient. If high doses are required, it is appropriate to give it in divided doses. Generally, if the 2 mg daily dose is not effective, it is thought that higher doses will be ineffective. In this case, the presence of colchicine resistance can be mentioned. While significant improvement is observed in 95% of patients with colchicine treatment, complete remission is achieved in 75% of the patients. Failure to take colchicine or taking less than the dose deemed appropriate for the patient may cause the onset of attacks. Steroids are ineffective in FMF attacks, but steroids should be added to the treatment in vasculitides that occur secondary to the disease. Immunosuppressant drugs such as cyclophosphamide should be started in cases that develop PAN (Polyarteisis nodosa).

5. Dental considerations

Recurrent oral aphthous ulcers, caries, and periodontitis can be seen as mouth findings in FMF (6). Extraoral findings are associated with temporomandibular joint (TMJ) involvement. Although rare, TMJ arthritis due to FMF can be seen (14). An important determinant of prognosis in FMF is the presence of amyloidosis. It develops in a minority of patients with FMF. It gradually accumulates in various tissues and organs, especially in the kidney. The diagnosis is made by demonstrating amyloid deposition by biopsy in the involved organ. Since chronic kidney disease poses a risk to oral health, it is known that oral health is inadequate in individuals with FMF who develop amyloidosis (3,5).

5.1. Periodontal disease

When the studies carried out to date in the literature are examined, it is seen that the relationship between FMF and periodontal disease is focused on (3-9). In terms of genetic and gender predisposition, periodontitis and FMF have been shown to have many similar potential pathogenic mechanisms. Both diseases have common risk factors such as smoking, age, social status, education and stress (9). In the study conducted by Fentoğlu et al. (8), on 122 FMF patients and 128 healthy controls, clinical periodontal parameters such as pocket depth on probing, plaque index, gingival index, bleeding on probing and clinical attachment loss were examined and it was shown that these values were lower in the M694V mutation. Sezer et al. (9) reported that there is a 3.51-fold higher risk of periodontitis in individuals with FMF with M694V gene mutation compared to other FMF patients, and they concluded that the risk of periodontitis is increased in FMF patients with M694V gene mutation. Fentoglu et al. (7) reported that rs2295368 and rs1380916375 polymorphisms are common in the PLG gene in the pathogenesis of FMF, amyloidosis and periodontitis, and that these diseases have a common pathogenesis. In another study (3), moderate to severe periodontitis was seen in FMF patients who developed amyloidosis, while milder periodontitis was seen in FMF patients who did not develop amyloidosis.

Colchicine is an alkaloid commonly used in the treatment of gout, FMF and other arthritis today. It is given in daily doses of 1-2 mg to keep inflammation and FMF attacks under control. Acute phase reactants rise during acute FMF attacks and return to normal during clinical remissions. It has been suggested that regular use of colchicine with its anti-inflammatory effect can prevent periodontal attachment loss (4). The need for additional treatment and the gingival index value of the patients who regularly use the drug were found to be significantly lower than the patients who did not use the drug.

Colchicine treatment is thought to be protective against periodontal damage, but the protective mechanism on periodontitis is not fully known. This protection is thought to be related to the regulatory effect of colchicine on osteoblast and osteoclast activity (13).

5.2. Tooth caries

In a study examining pediatric patients with FMF (13), the prevalence of dental caries in patients who had and did not have an attack in the last 6 months was examined. The percentage of patients who had any dental caries in the last 6 months was found to be significantly higher than the rate of any tooth decay in the patients who did not have an attack in the last 6 months. The presence of M694V homozygous gene mutation was found to have a significantly higher percentage of primary tooth caries and susceptibility to any dental caries than its absence, and they reported that dental caries and periodontal diseases were seen with a high frequency in individuals with FMF.

5.3. Oral aphthous ulcer

It is known that aphthous ulcers are frequently seen in autoimmune diseases (6). In a study (18) in which 586 patients diagnosed with FMF were examined, diseases accompanying FMF were investigated, and it was reported that Behçet's disease, which is accompanied by oral and genital aphthae, is among the diseases accompanying FMF.

Dysregulation of cellular immunity is accused in the etiology of recurrent aphthous ulcers, and colchicine has been reported to be effective in the treatment of aphthous ulcers by binding to microtubular proteins (6).

5.4. Other considerations (Tongue, lip, oro-dental anomalies and TMJ arthritis)

The tongue is a localized site of intraoral amyloid deposition (19). Similarly, the lip may become prominent in FMF patients as a result

of chronic inflammation. In individuals with FMF, the ramus height is lower and the mandible is smaller (20). Bone mineral density decreases as a result of chronic inflammation and developmental defects (deep bite, mandibular prognathia, maxillary hypoplasia) can be observed (21). Decreased mineral density in the bone and vitamin D deficiencies, which are common in individuals with FMF, are shown as the cause of enamel defects (22-24).

Although TMJ involvement is rare in FMF, it significantly reduces the quality of life and may be misdiagnosed due to similar symptoms with some diseases. FMF that causes TMJ arthritis is usually short-lived. However, it can persist for months, causing bone damage such as chronic pain, trismus, and juxta-articular osteoporosis. In the literature, methods such as anesthetic spray, physiotherapy, IM local anesthesia injection, arthrocentesis, therapeutic exercises, IM and intra-articular dexamethasone injection, arthroscopy have been reported in the treatment of cases with FMF-related TMJ arthritis. In all reported cases, patients have reduced symptoms, but there is no definitive treatment consensus (14).

Conclusion

Oral hygiene motivation should be given to these patients and routine follow-up should be performed by dentists, especially considering the predisposition to periodontitis, dental caries and oral aphthous ulcer in FMF patients.

References

1. Tunca M, Akar S, Onen F, et al. Familial Mediterranean fever (FMF) in Turkey: results of a nationwide multicenter study. Medicine (Baltimore) 2005; 84(1): 1–11.

2. Guncu GN, Caglayan F. Resolution of anterior scleritis after periodontal therapy. Eur J Dent 2011; 5: 337–339

3. Cengiz MI, Bagci H, Cengiz S, Yigit S, Cengiz K. Periodontal disease in patients with familial Mediterranean fever: from

inflammation to amyloidosis. J Periodontal Res. 2009;44(3):354-361.

4. Bostancı V, Toker H, Senel S, Sahin S. Prevalence of periodontal disease in patients with Familial Mediterranean Fever: a cohort study from central Turkey. Quintessence Int. 2014;45(9):743-748.

5. Cengiz M, Yayla N, Cengiz K, Bagci H, Taşkın E. Interaction between periodontal disease and systemic secondary amyloidosis: from inflammation to amyloidosis. J Periodontol. 2011;82(4):566-574.

6. Esmeray P, Keçeli Tİ, Tekçiçek M, et al. Oral health status in children with familial Mediterranean fever. Turk J Pediatr. 2021;63(3):443-9.

7. Fentoğlu Ö, Tülüceoğlu EE, Orhan H. Plasminogen gene polymorphisms [c.924C>T and IVS 8+14 G>A] in periodontitis and familial Mediterranean fever: A case-control study. J Periodontal Res. 2022;57(2):371-380.

8. Fentoğlu Ö, Dinç G, Bağcı Ö, et al. R202Q/M694V as novel MEFV gene mutations in chronic periodontitis and familial Mediterranean fever. J Periodontal Res. 2017;52(6):994-1003.

9. Sezer U, Şenyurt SZ, Özdemir E, et al. Relationship between periodontal destruction and gene mutations in patients with familial Mediterranean fever. Clin Rheumatol. 2016;35(7):1841-1847.

10. Ben-Chetrit E, Touitou I. Familial Mediterranean fever in the world. Arthritis Rheum 2009; 61(10): 53-1447

11. Yalcınkaya F, Orun E. Türk tıbbında ailevi akdeniz ateşi hastalığı ve amiloidoz. Türk Nefroloji Diyaliz ve Transplantasyon Dergisi 2003; 12 (1): 1-7

12. Tunca M, Ben-Chetrit E. Familial Mediterranean fever in 2003. Pathogenesis and management. Clin Exp Rheumatol 2003; 21(4): 49-52

13. Esmeray P. Pediatrik AAA (Ailevi Akdeniz ateşi) hastalarında yaş gruplarına göre hastalığın klinik özelliklerinin, aktivitesinin ve ağız-diş sağlığı durumunun değerlendirilmesi.

Hacettepe Üniversitesi Tıp Fakültesi, Çocuk Sağlığı ve Hastalıkları Anabilim Dalı, Uzmanlık Tezi, Ankara, 2016 (Tez Danışmanı: Prof. Dr. Yelda Bilginer)

14. Ak KB, Suzen M, Uçkan S. Aseptic Arthritis of the Temporomandibular Joint with Severe Inflammation in an FMF Patient: A Case Report. Journal of Anatolian Medical Research. 2022;7(1):35-40.

15. Üstebay S, Üstebay DÜ, Yılmaz Y. Ailevi Akdeniz Ateşi. JAREM. 2015;5(3):89-93.

16. Sarı O. Birinci basamakta ailevi Akdeniz ateşine genel yaklaşım. Konuralp Medical Journal. 2013;5(2):75-80.

17. Zemer D, Livneh A, danon YL et al. Long-term colchisine treatment in children with Familial Mediterranean Fever. Arthritis Rheum 1991;34:973–977.

18. Kısaarslan Paç A, Özdemir Çiçek S,Şahin N, Taşkın SN, Poyrazoğlu H, Gündüz Z, Düşünsel R. Ailevi Akdeniz Ateşi Tanısına Eşlik Eden Hastalıklar: Tek Merkez Deneyimi. Bozok Tıp Dergisi, 10.2: 105-110.

19. Madani M, Harwick RD, Chen SY, Miller AS. Amyloidosis of the oral cavity: report of five cases. Compendium. 1991;12(5):336, 338-342.

20. Gungor AY, Arica V, Gungor O, Tutanc M. Cephalometric evaluation of children with familial Mediterranean fever. Angle Orthod. 2012;82(3):552-555.

21. Duzova A, Ozaltin F, Ozon A, et al. Bone mineral density in children with familial Mediterranean fever. Clin Rheumatol. 2004;23(3):230-234.

22. Skeie MS, Gil EG, Cetrelli L, et al. Oral health in children and adolescents with juvenile idiopathic arthritis - a systematic review and meta-analysis. BMC Oral Health. 19 2019;19(1):285.

23. Botelho J, Machado V, Proenca L, Delgado AS, Mendes JJ. Vitamin D Deficiency and Oral Health: A Comprehensive Review. Nutrients. 2020;12(5).

24. Mohamed R, El-Bassyouni HT, Elwan SH, et al. Carotid intima-media thickness, lipid profile, serum amyloid A and vitamin D status in children with familial Mediterranean fever. Egyptian Rheumatologist. 2020;42(3):237-240.